



Dr. M.Veliky

KPCH FNB

Doc.Dr.Mestak J.CSc

přednosta KPCH FNB

# Ztráty kožního krytu prstu-místní lalokové plastiky.

Klinika plastické chirurgie  
1.LF a Fakultní nemocnice Na Bulovce

Praha 5.5.2005

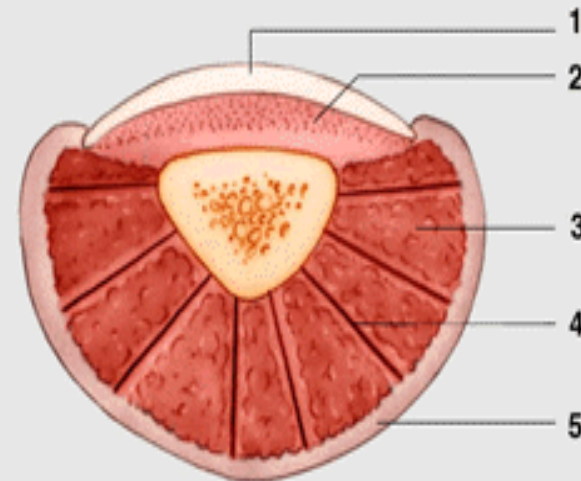
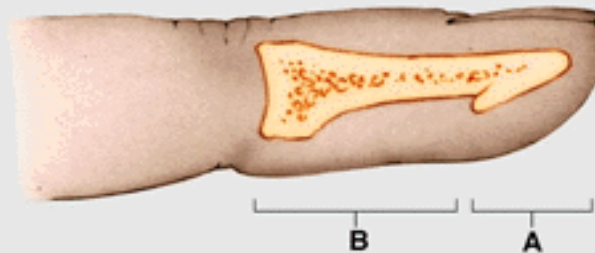
# Anatomie distalního clanku prstu

2 funkční jednotky

A=distální pulpa

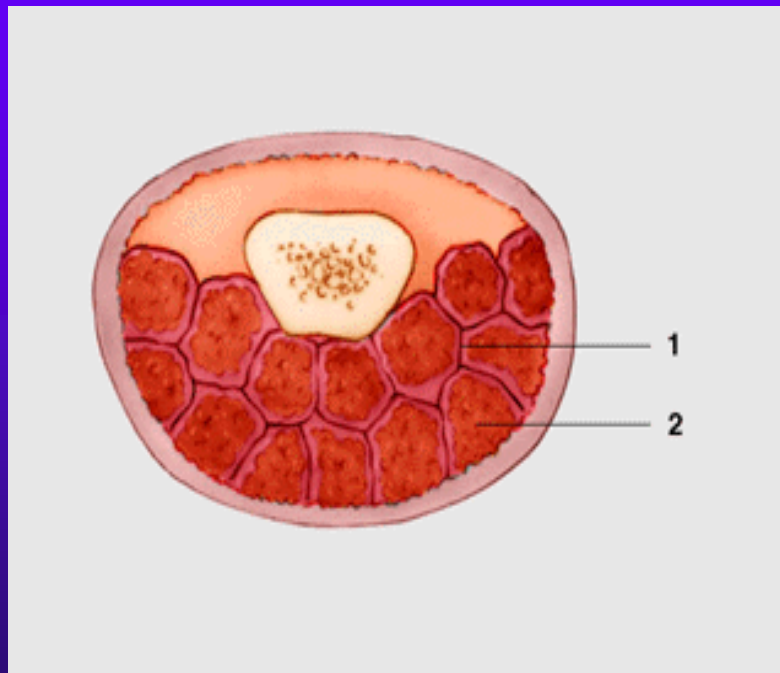
B=proximální pulpa

- ♦ Distální pulpa na rezu
- ♦ Nehet, luzko, fibrosní septa, kuze

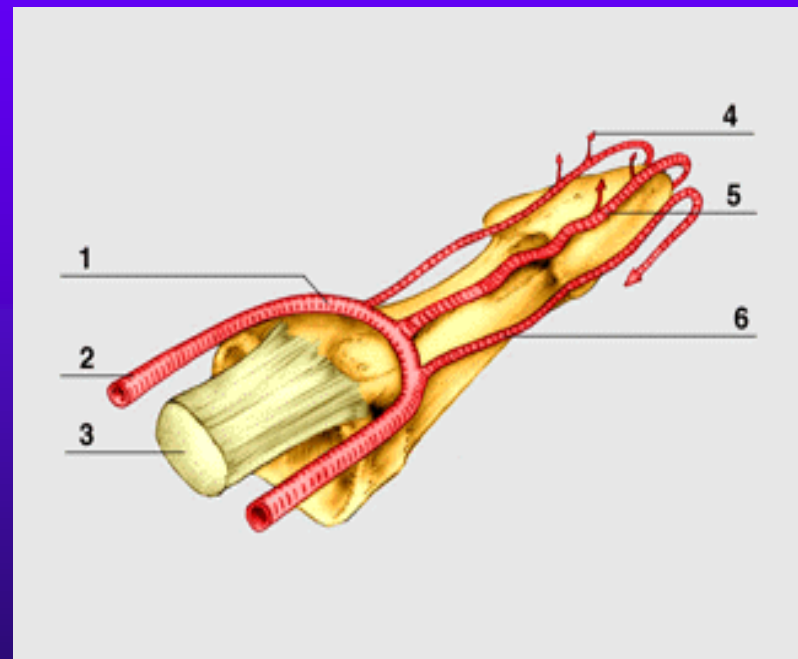




- ◆ Prox.pulpa na transversalnim rezu

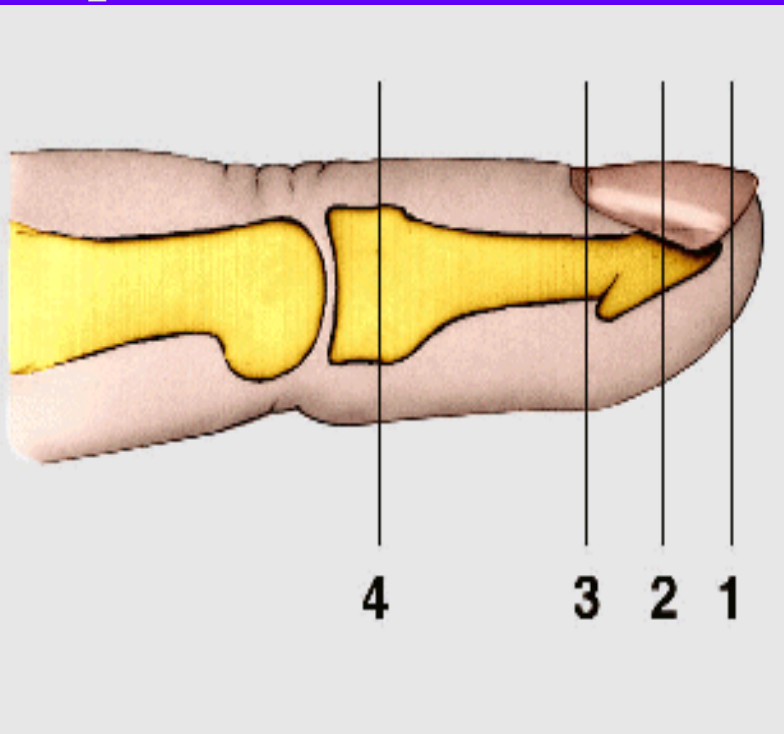


- ◆ Vascularizace distalního clanku3





## ◆ Distalni amputace prstu



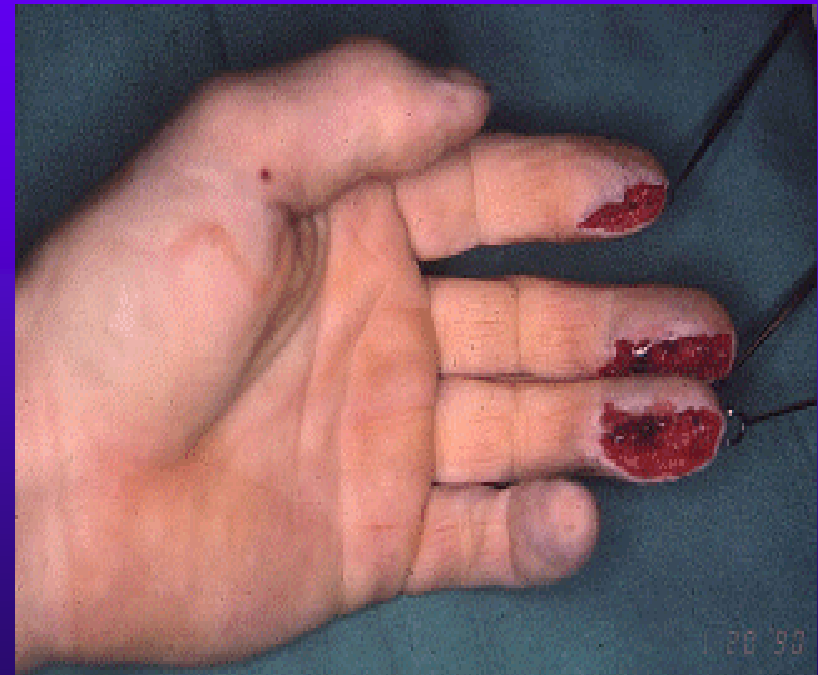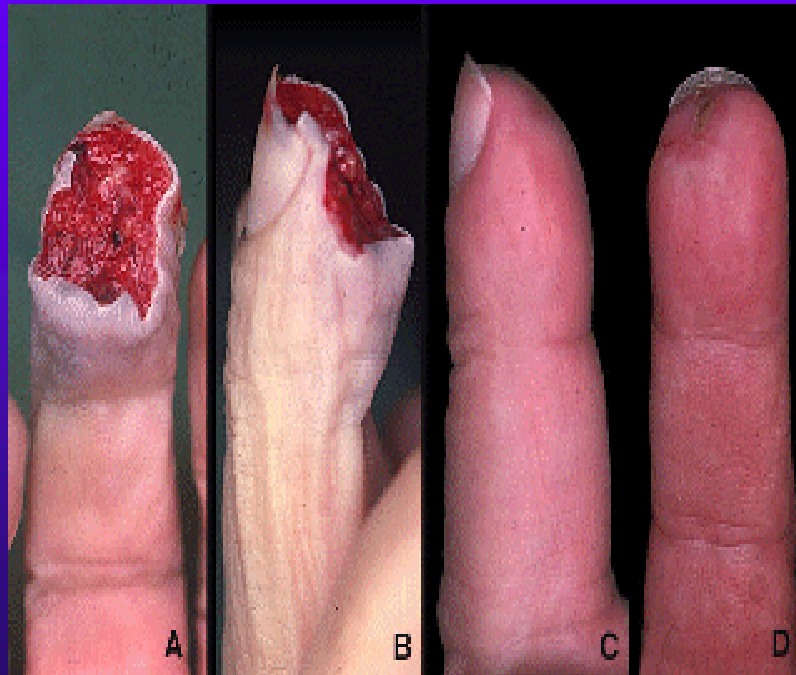
- ◆ 1.dist.amputace bez expozice kosti- granulace
- ◆ 2.amputace na urovni nehtoveho luzka- replantace, nehet roste bez pazouroviteho zahnuti
- ◆ 3.amputace na urovni zarodecni matrix- sterilizace zar.zony v uvahu
- ◆ 4.replantace, lze li



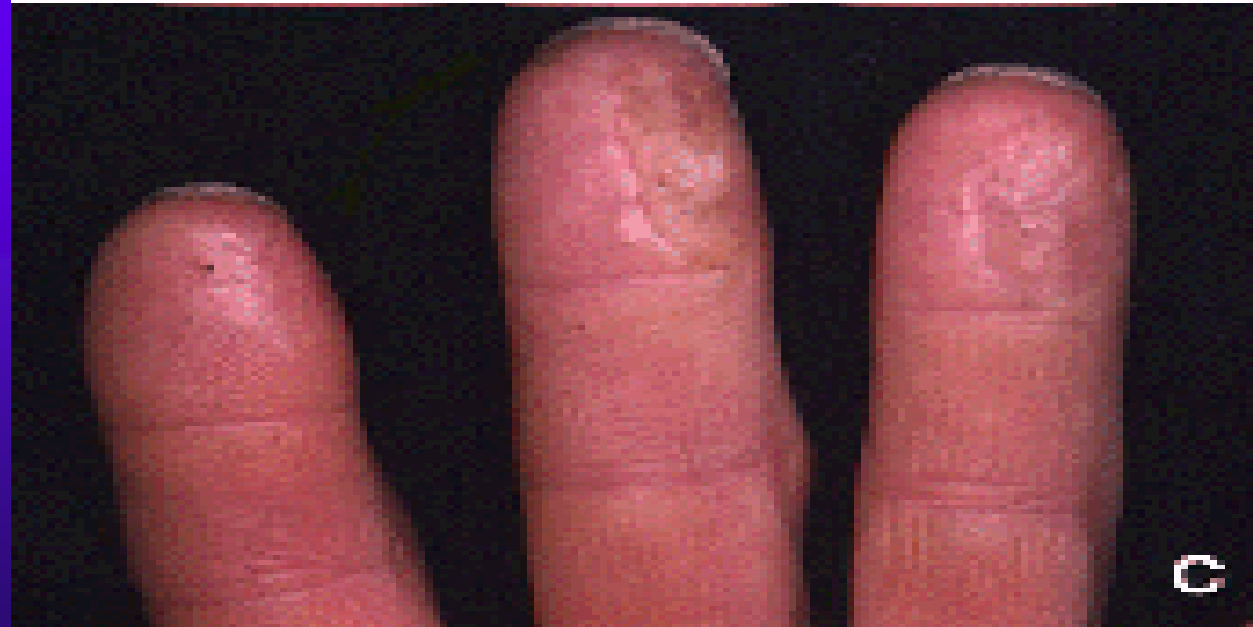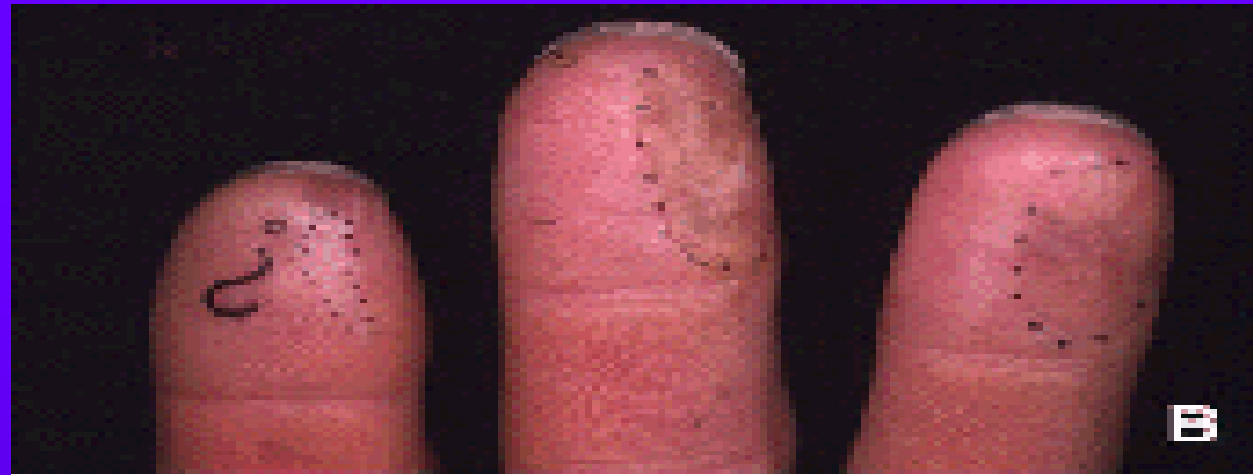# Moznosti reparace ztraty kozniho krytu

- ◆ Granulace & epitelizace
- ◆ Kozni step v plne tloustce
- ◆ Mistni lalokova plastika
- ◆ Replantace (nutnost znalosti mikrochirurgicke techniky)
- ◆ Kombinace (lalokova plastika + step...)

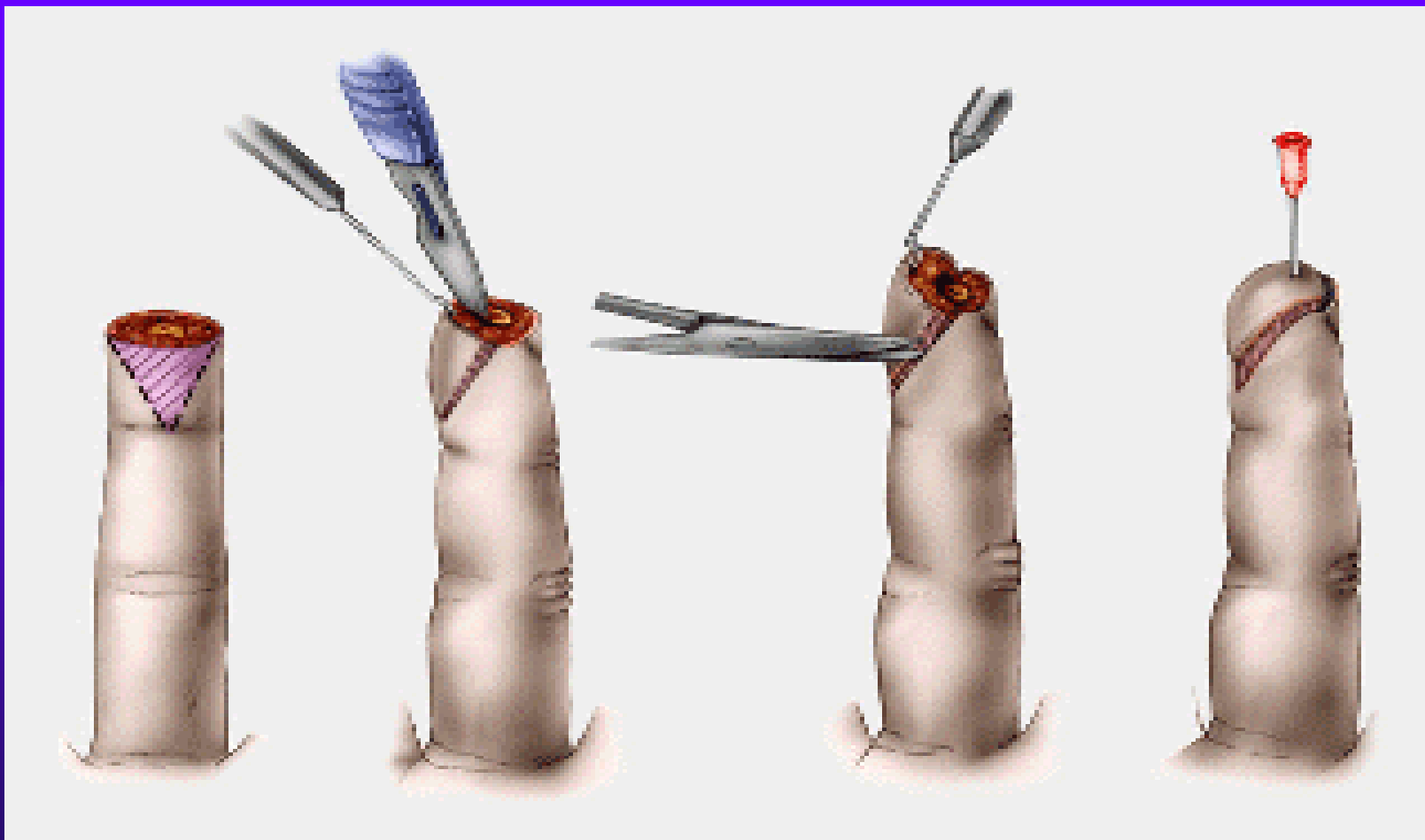
# Rizena granulace+epitelizace





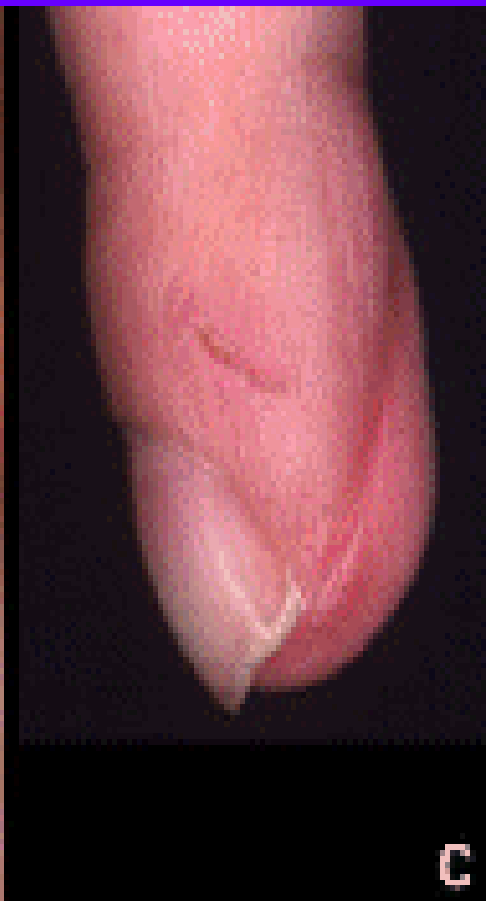
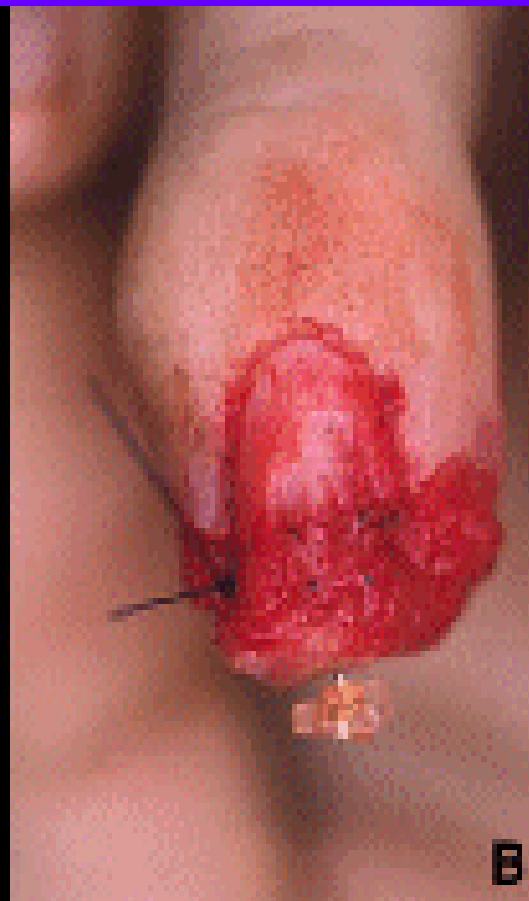
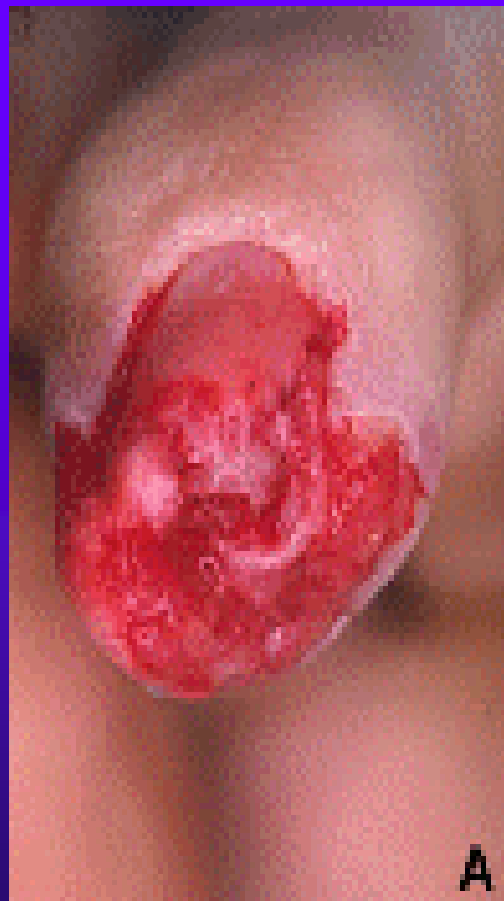# Atasoyuv lalok



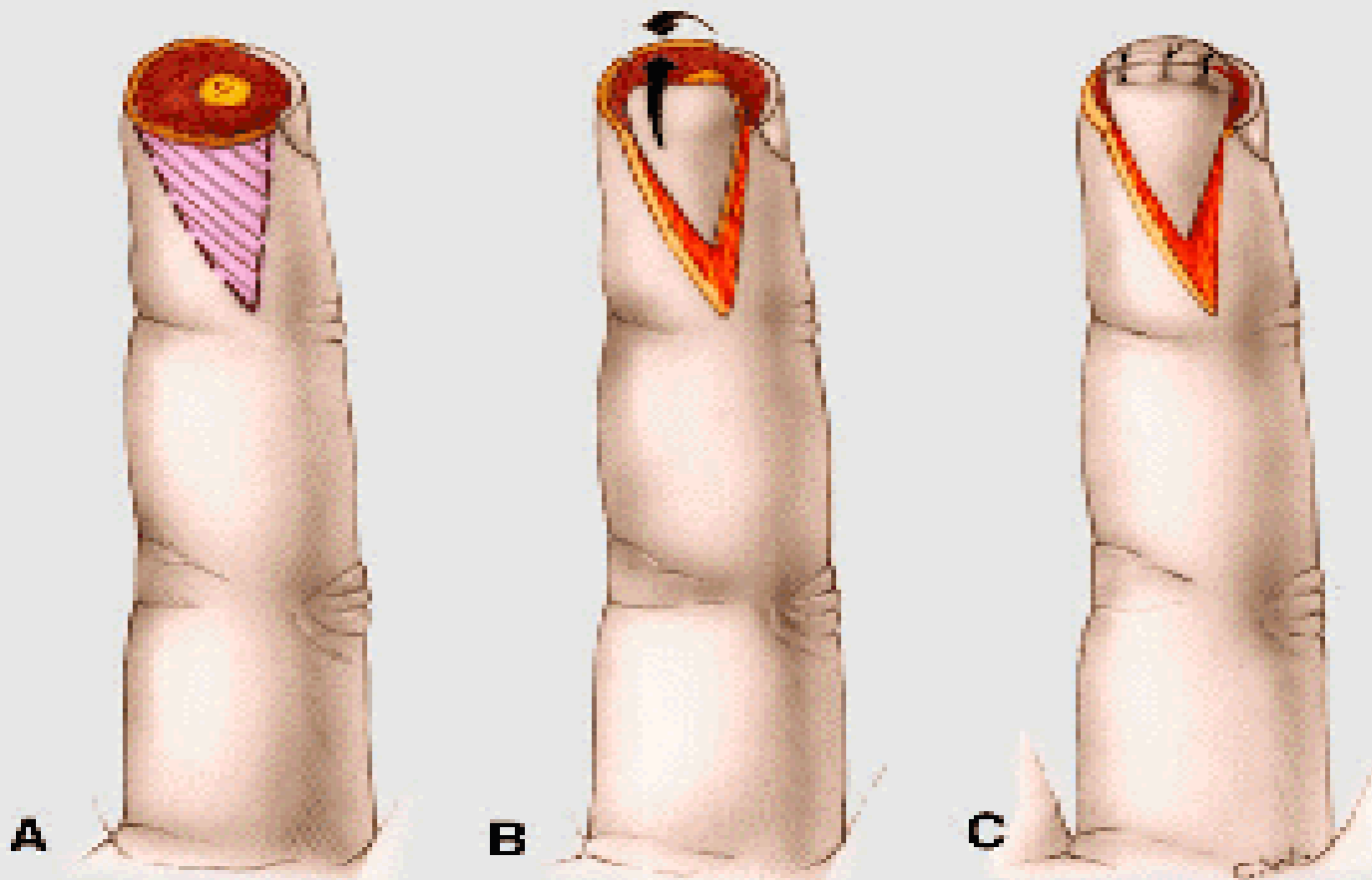


# Atazoyuv lalok

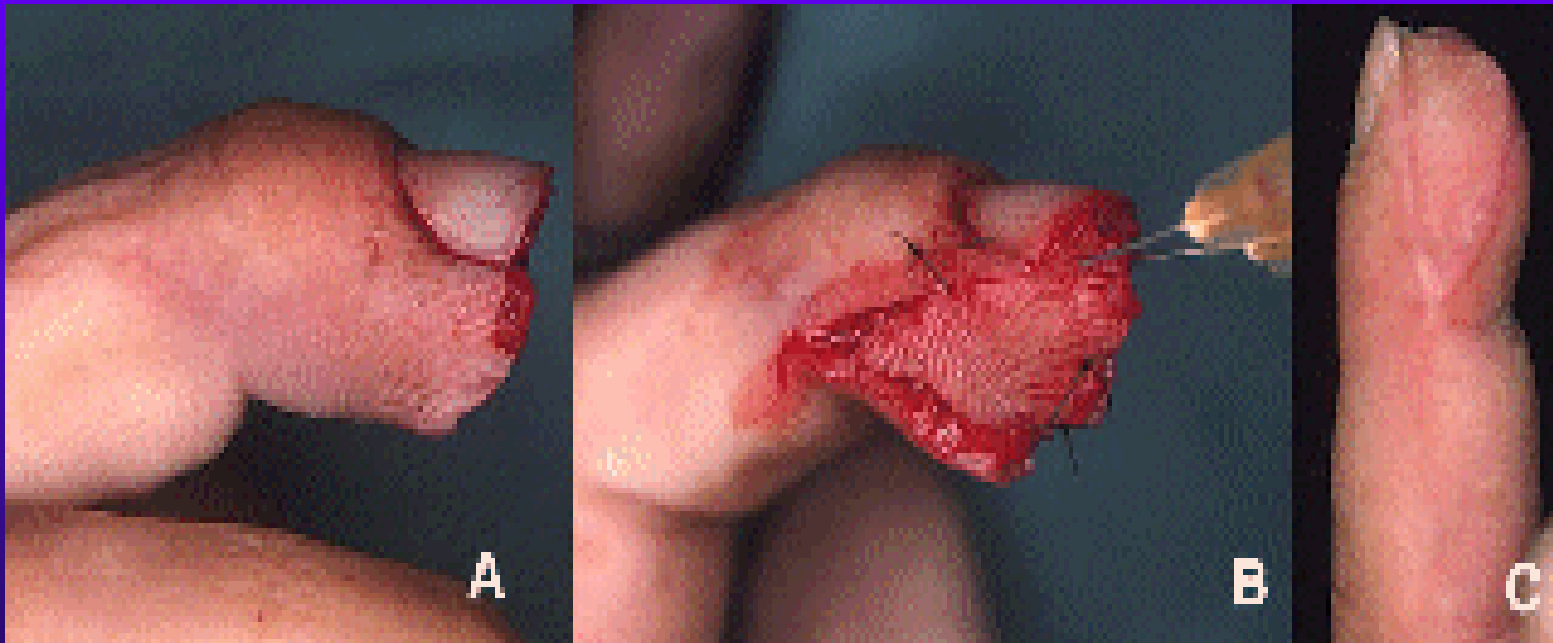




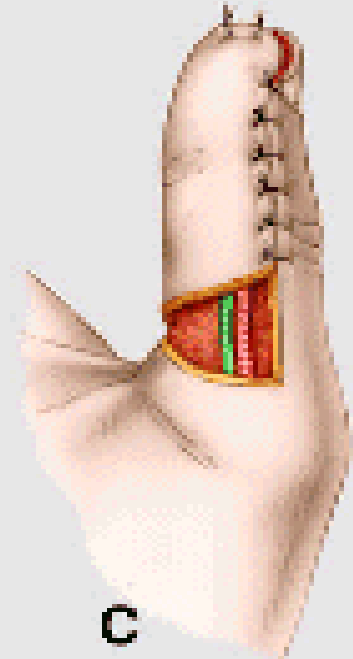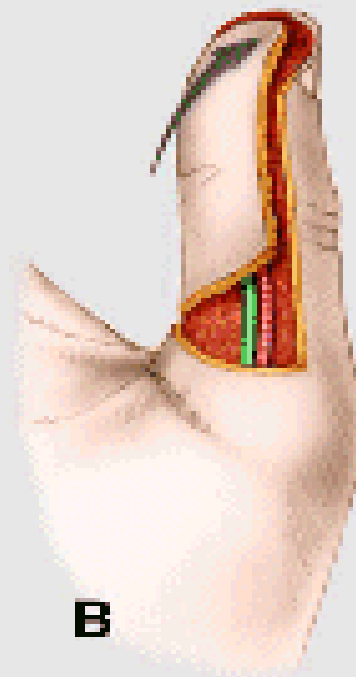


# Kutleruv lalok



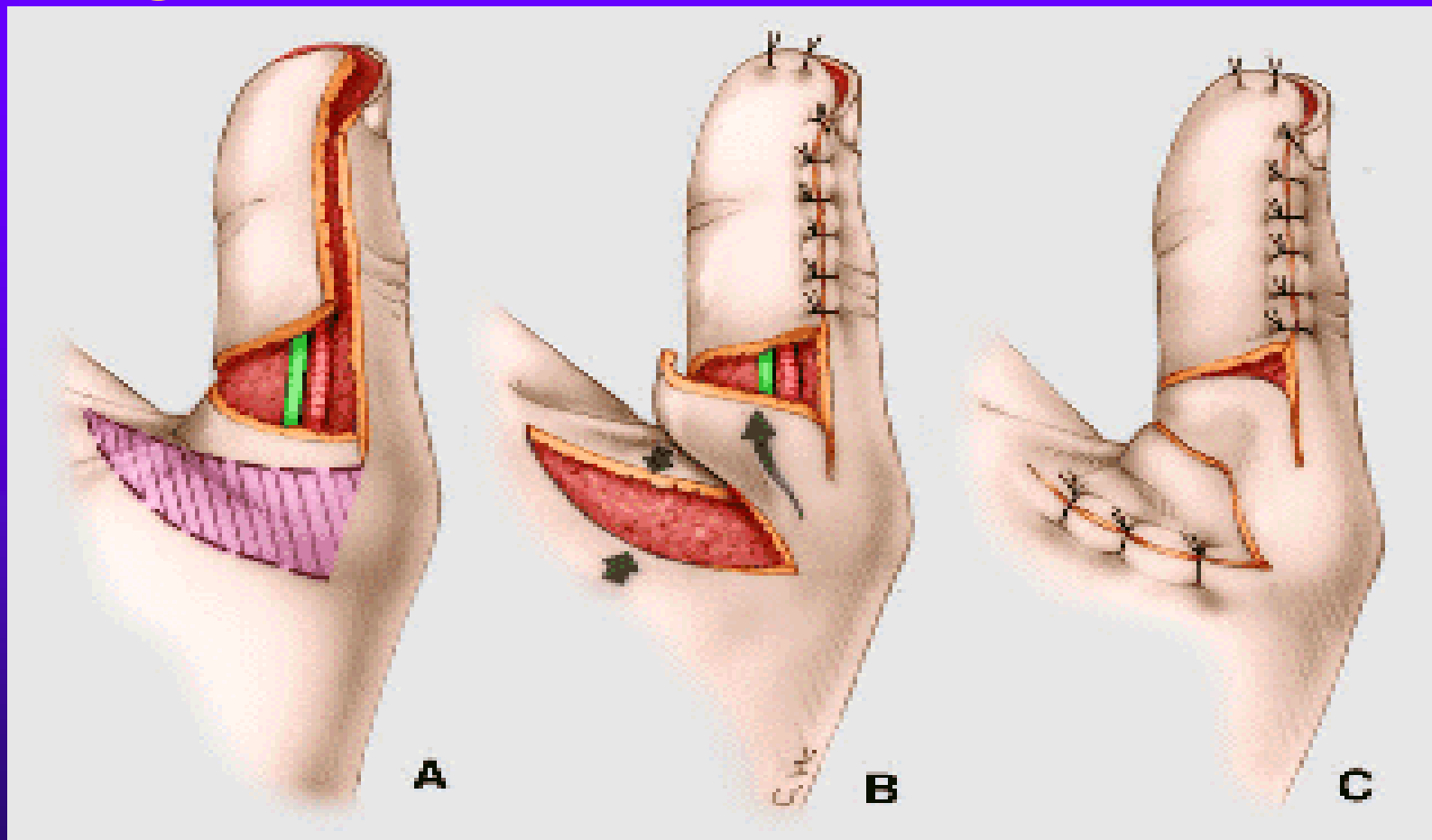
# Kutleruv lalok



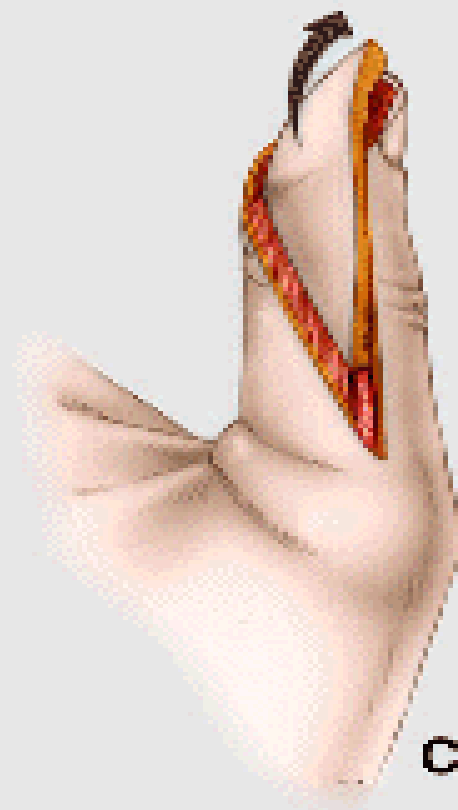
# Huestonuv lalok



# Huestonuv lalok-modifikace dle Argamaso

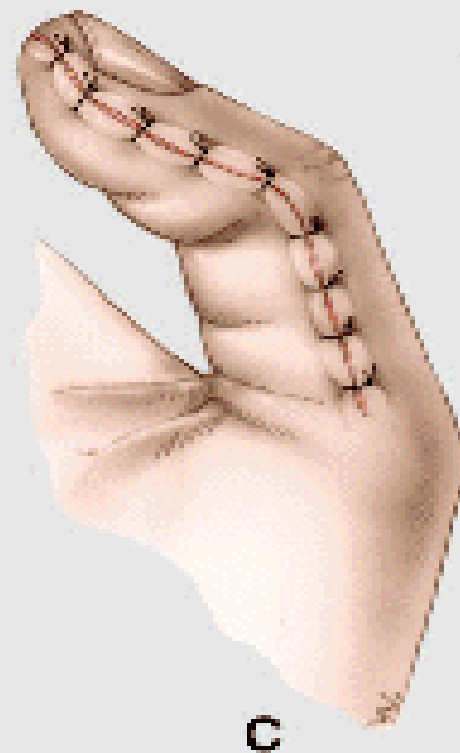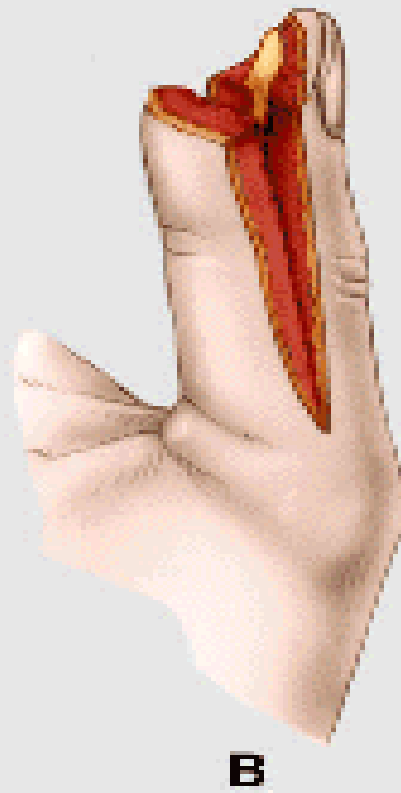



# Lalok podle Venkataswami & Subramanian

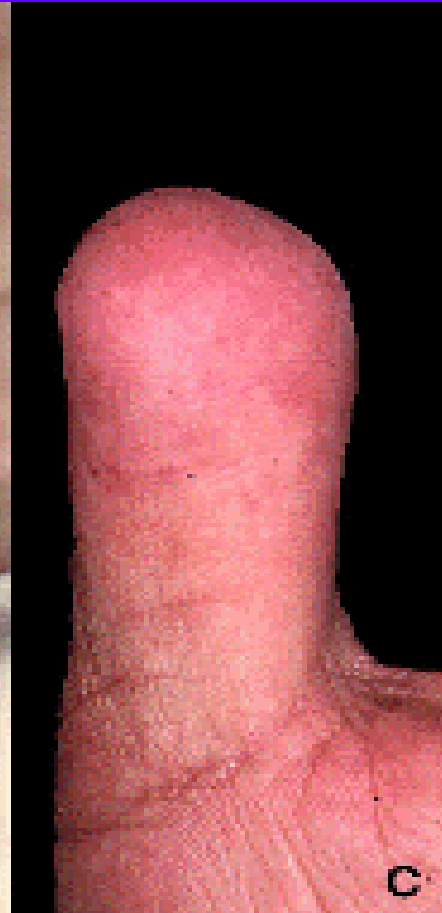
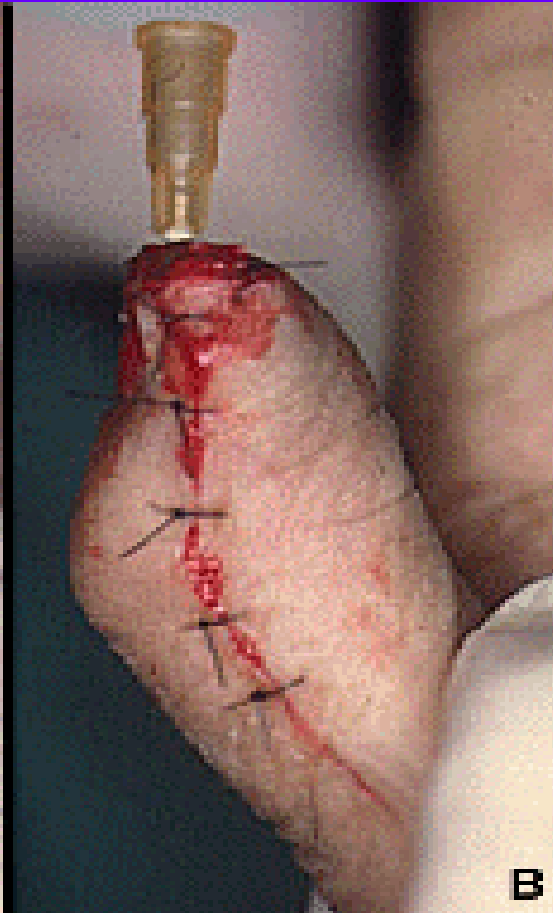
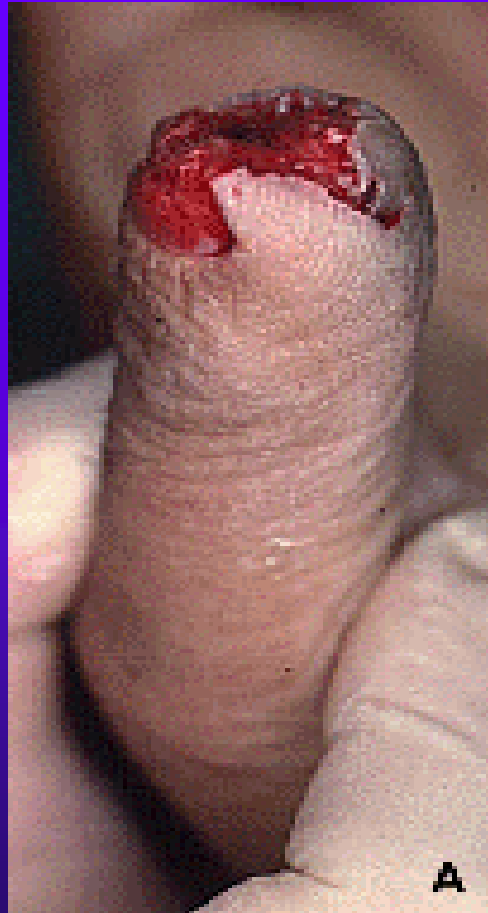



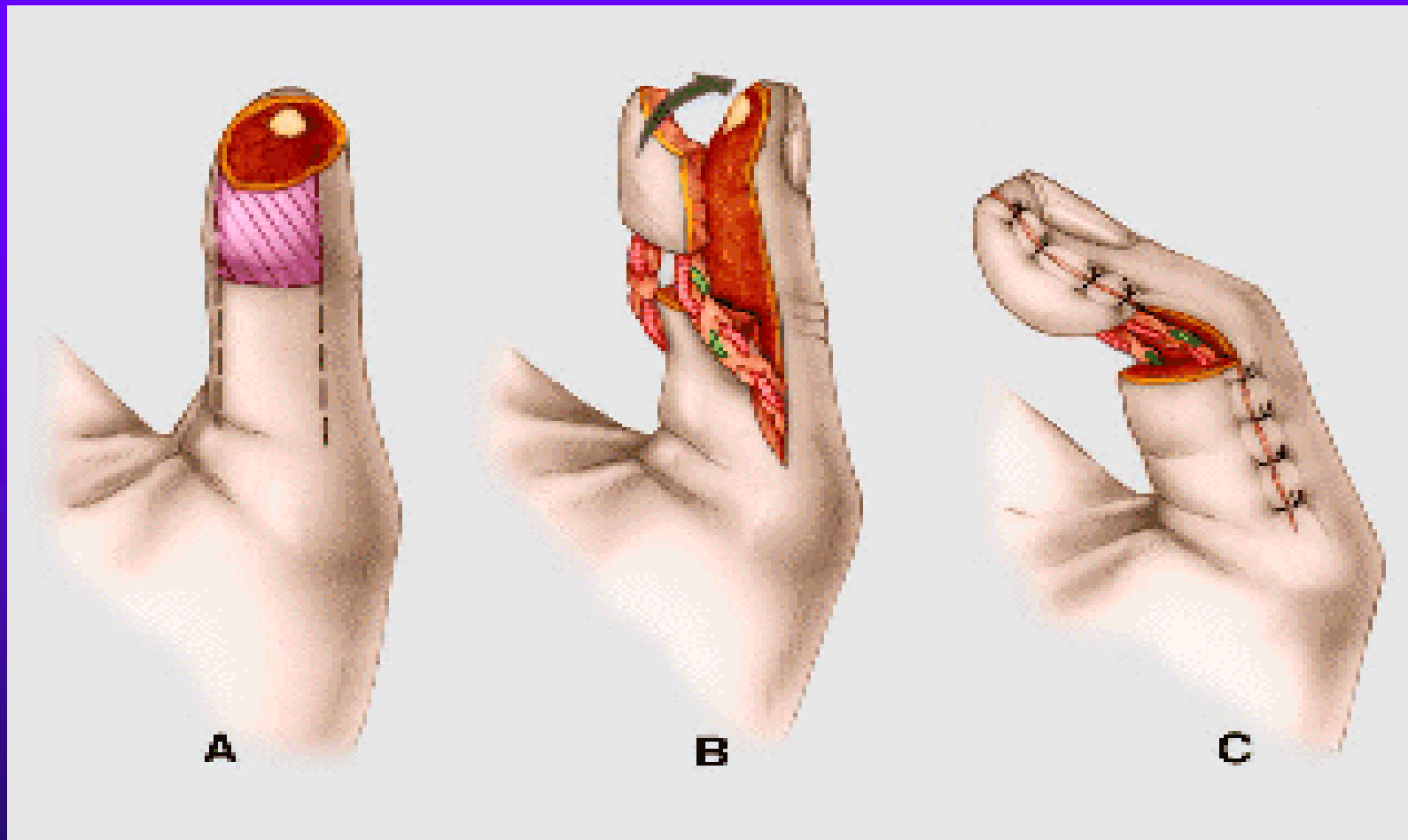
# Möberguv lalok ( pouze pro palec)



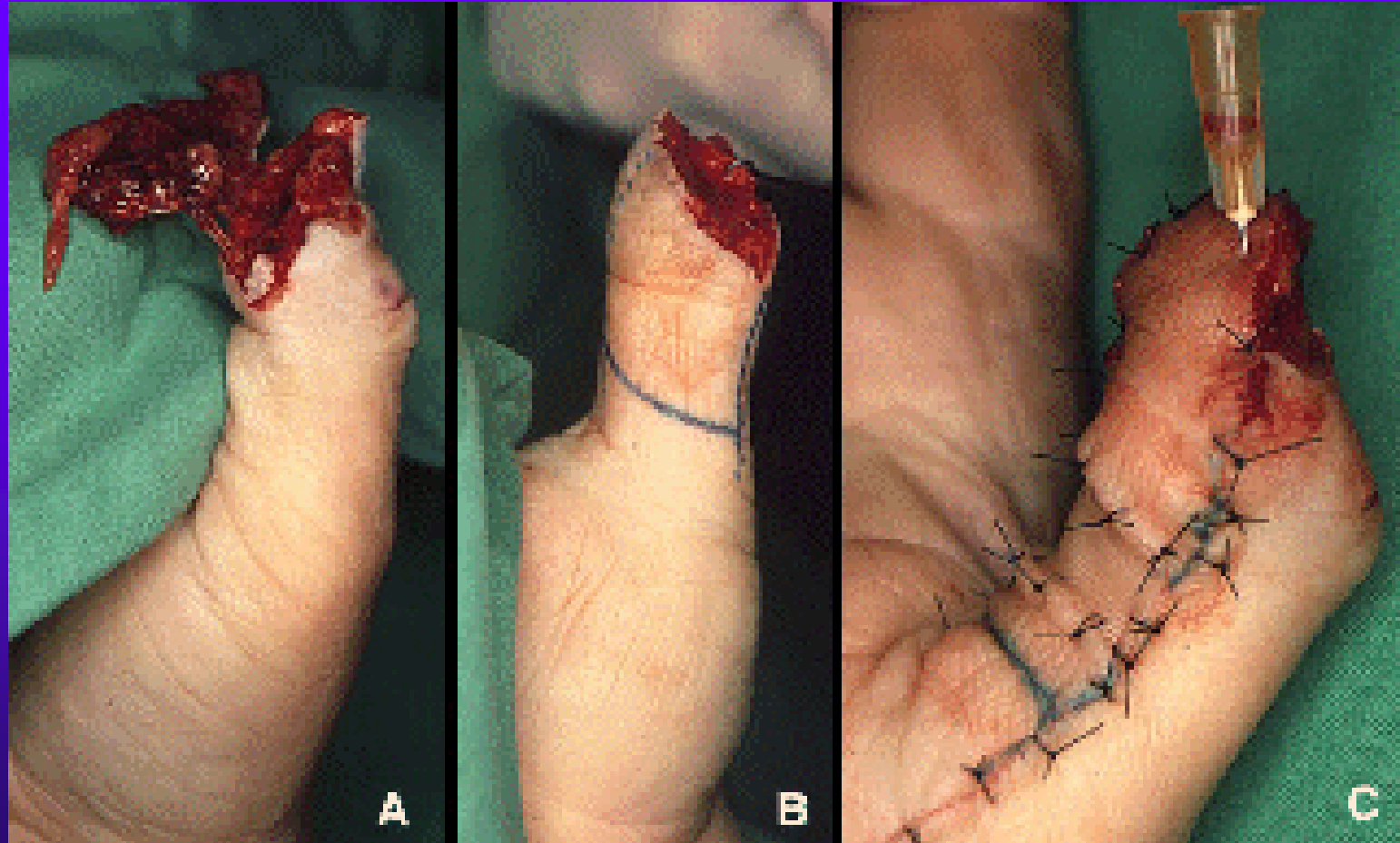
# Möberguv lalok



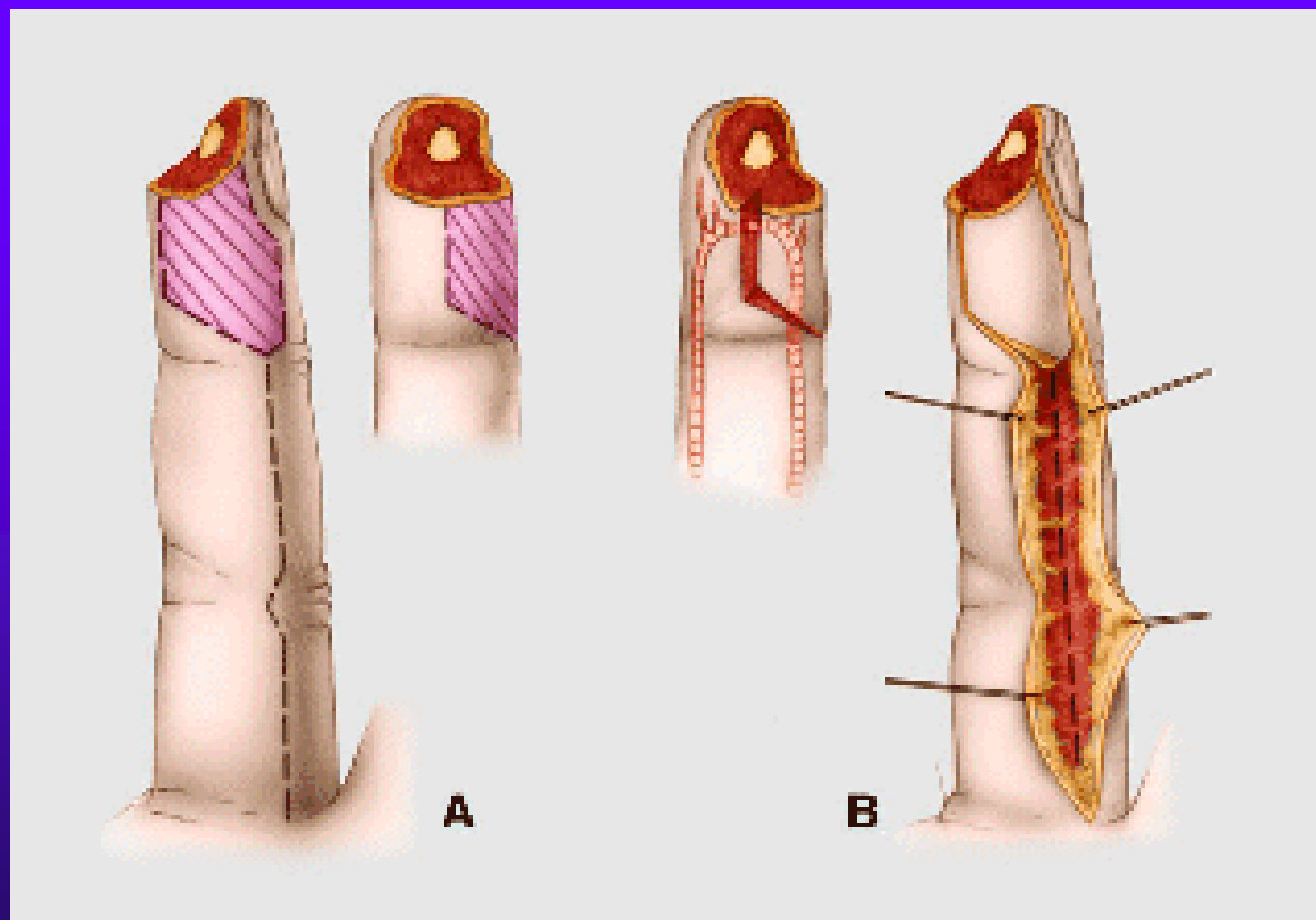
# O'Brienov lalok

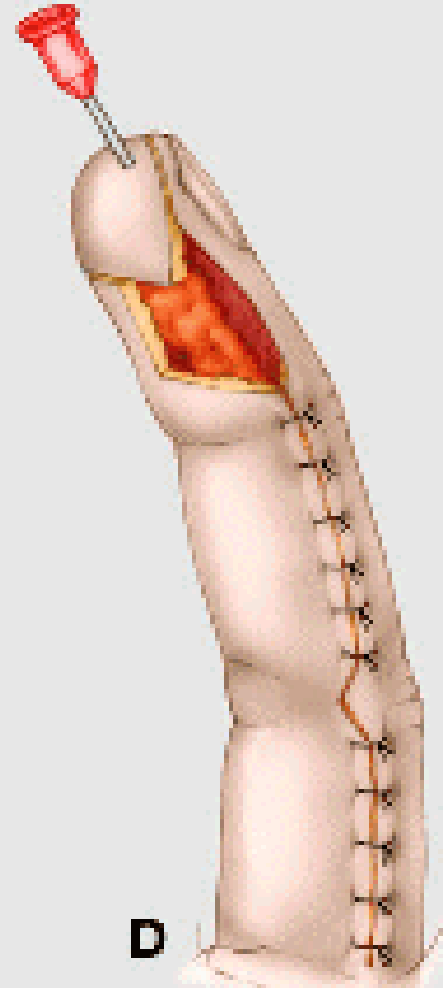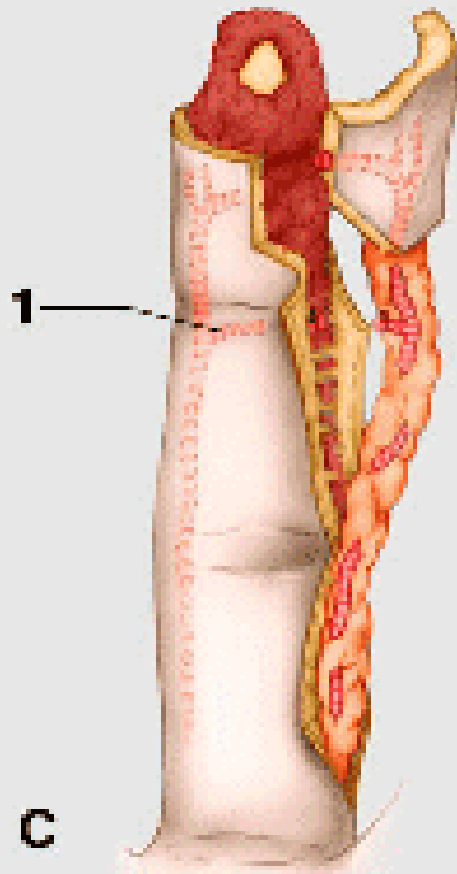


# Möberguv lalok



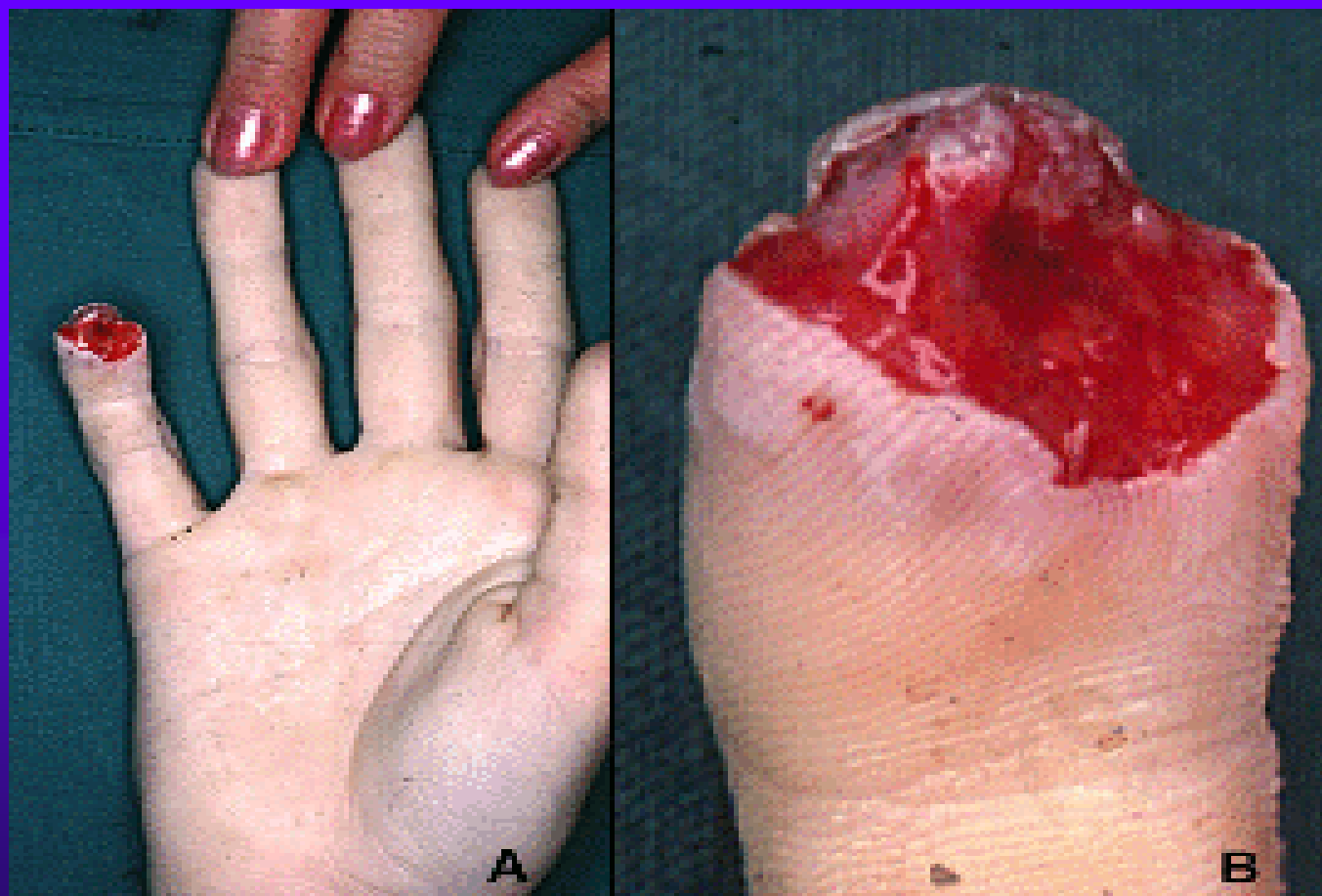# Pulparni stopkaty homodigitalni lalok



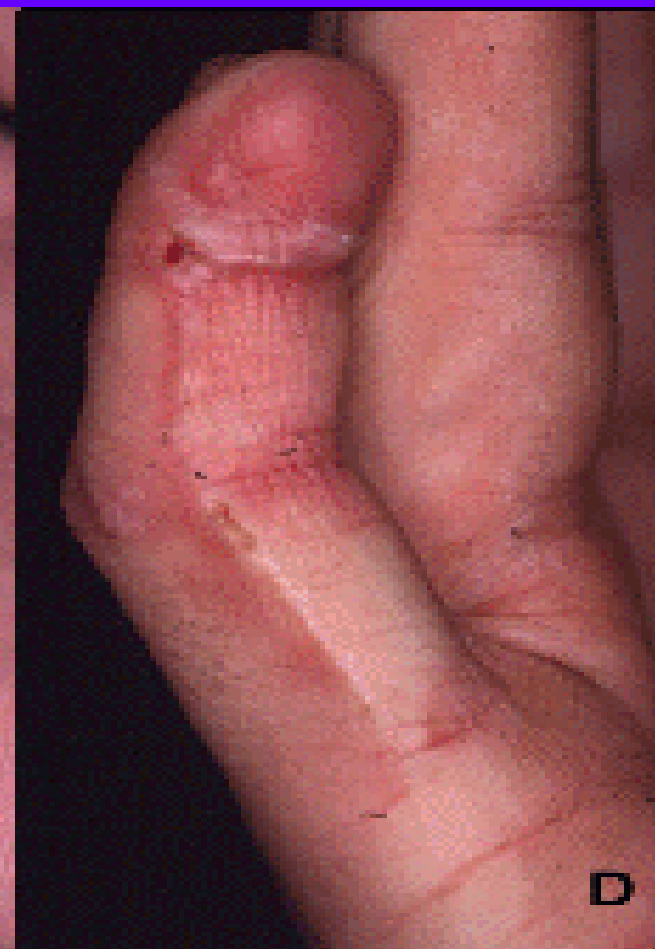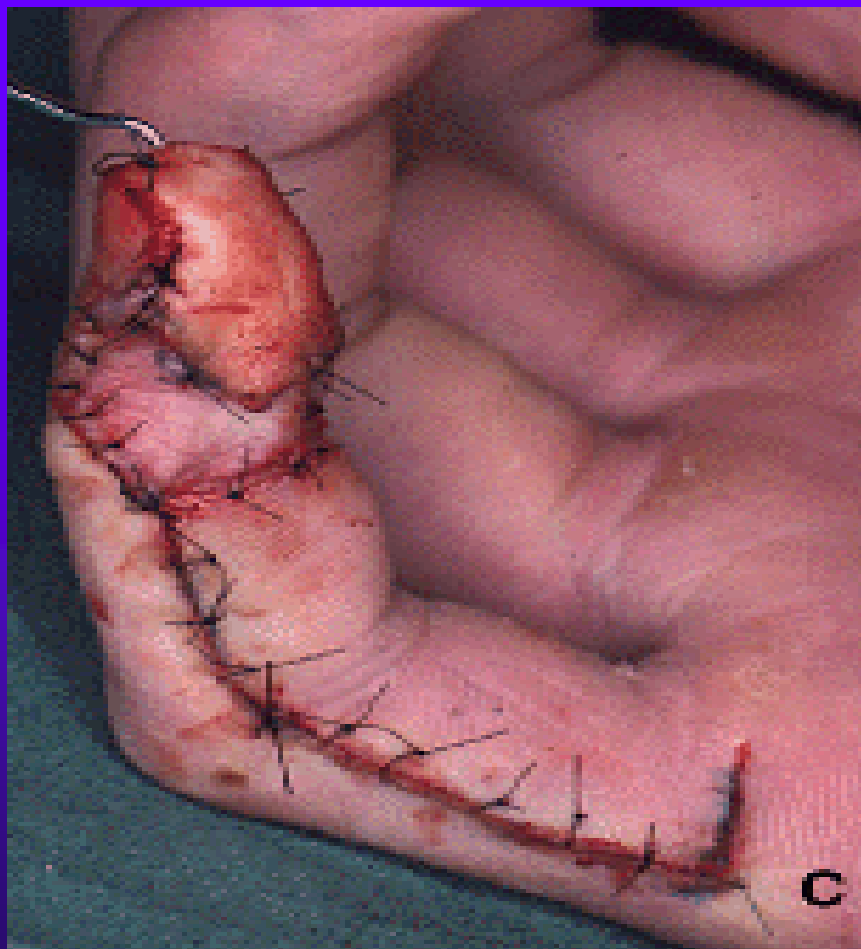




# Pulparni homodigitalni stopkaty lalok

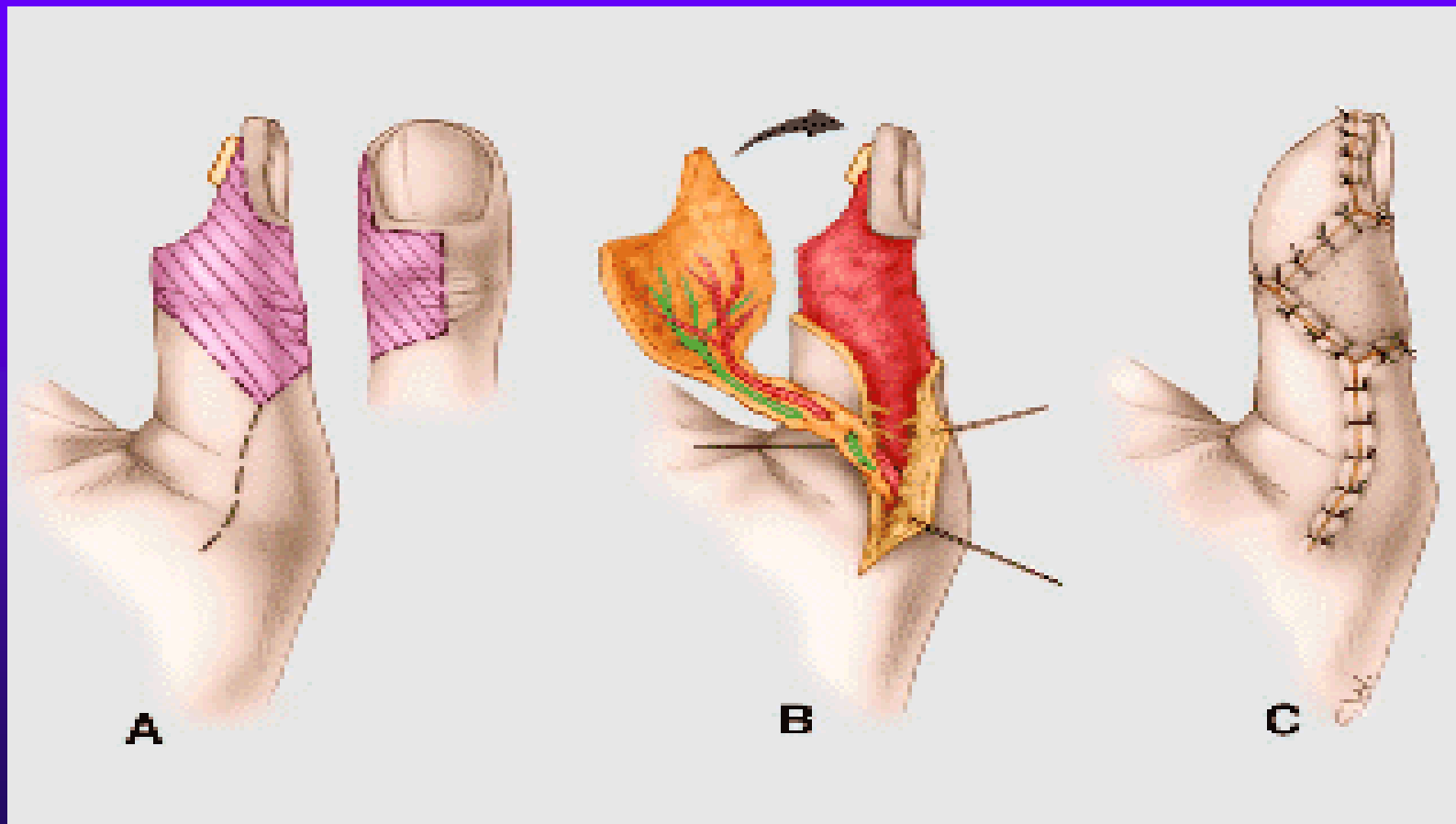


# Pulparni stopkaty homodigitalni lalok

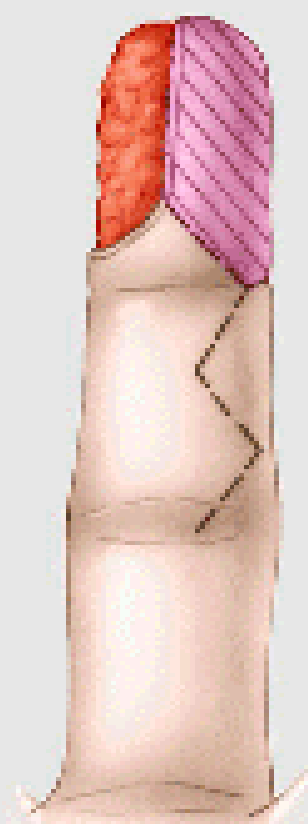

# Lalok podle Joshi & Pho

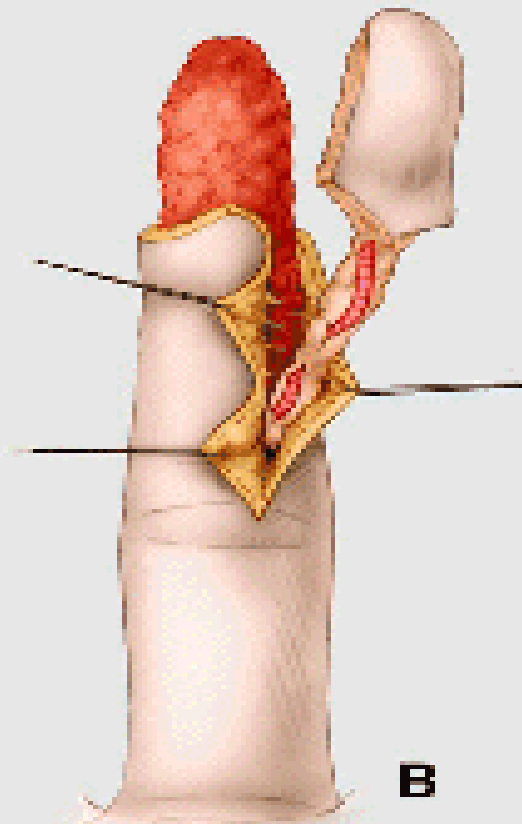
(2 i 3-clankove prsty, modifikace  
pulparniho homodigitalniho laloku)



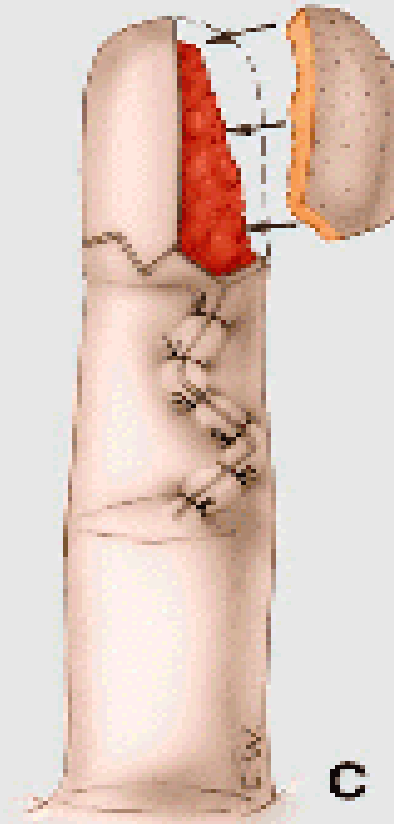
# Lalok vymenou pulpy



**A**

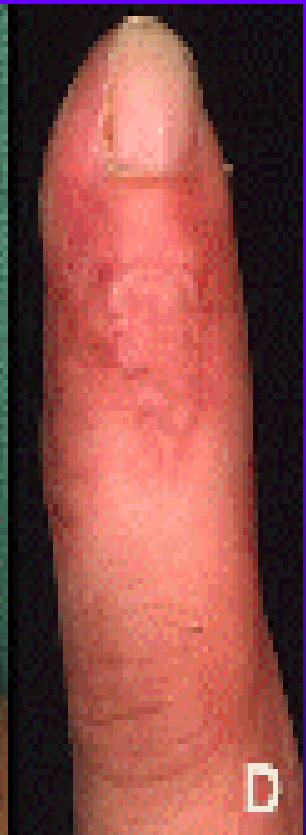
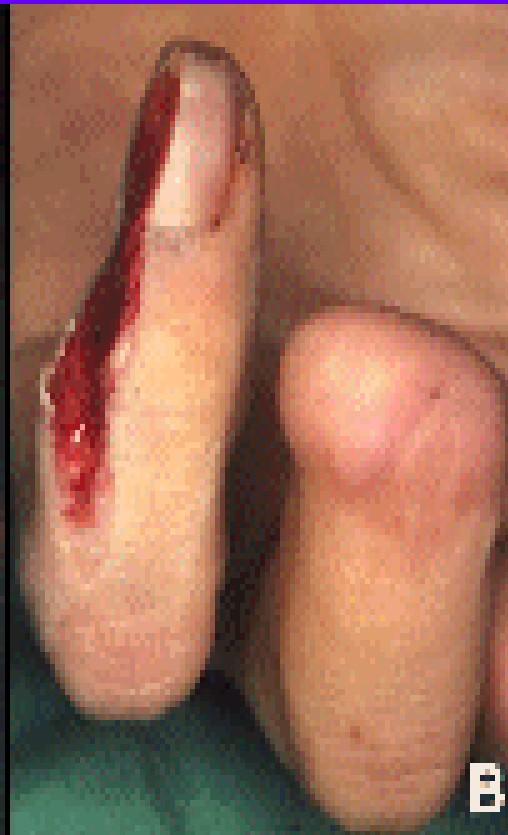
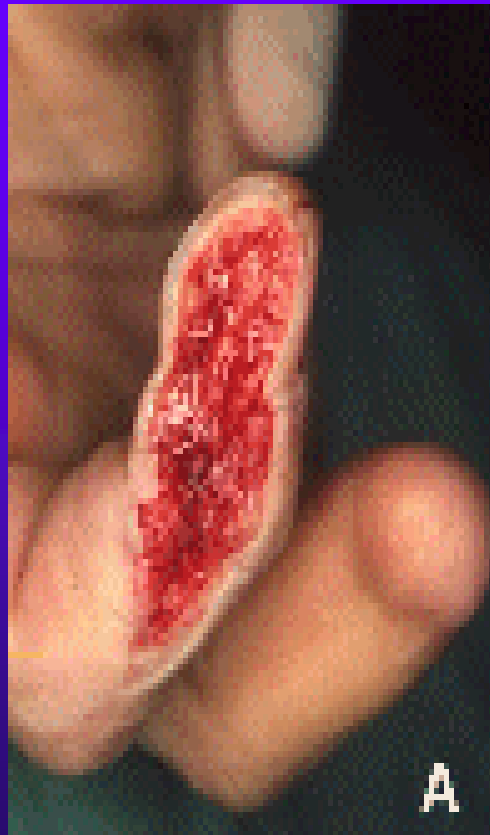
**B**

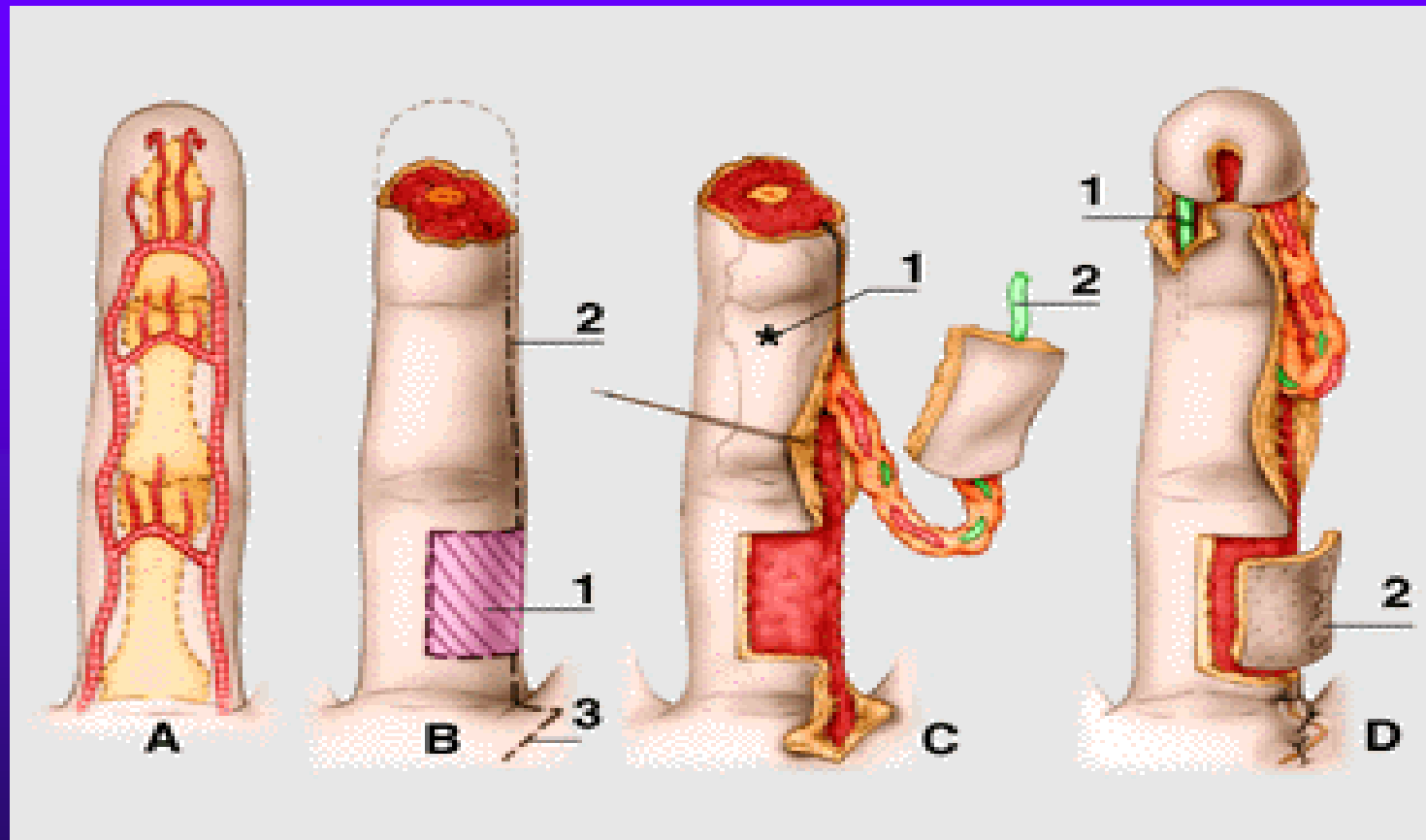


**C**

# Lalok vymenou pulpy

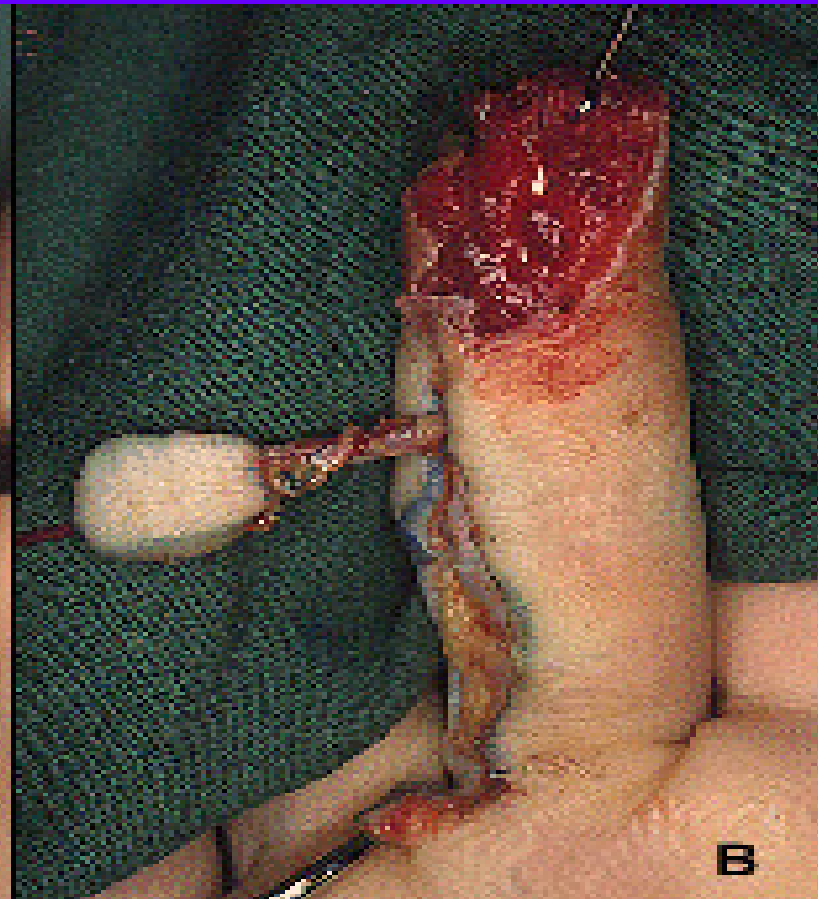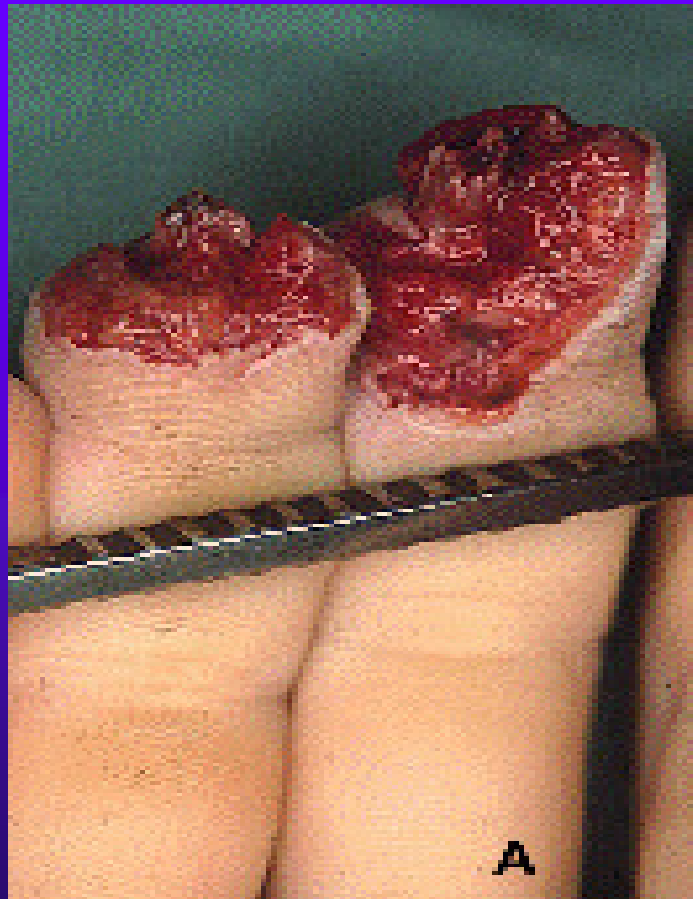


# Homodigitalni stopkaty resenzibilizovany lalok « à contrario »



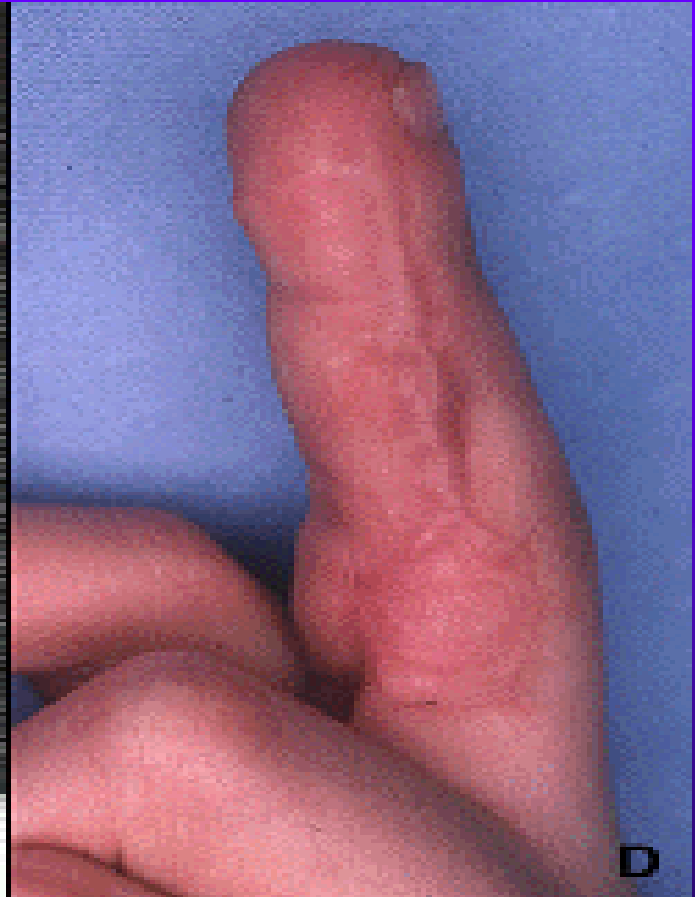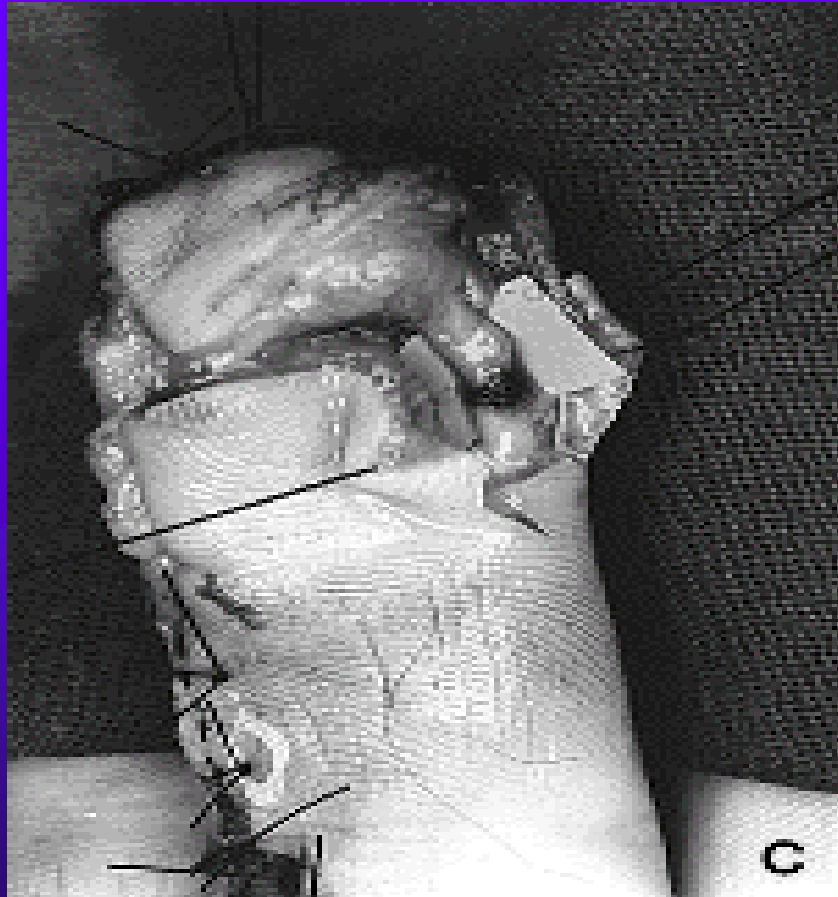


# Homodigitalni stopkaty resensibilizovany lalok « à contrario »



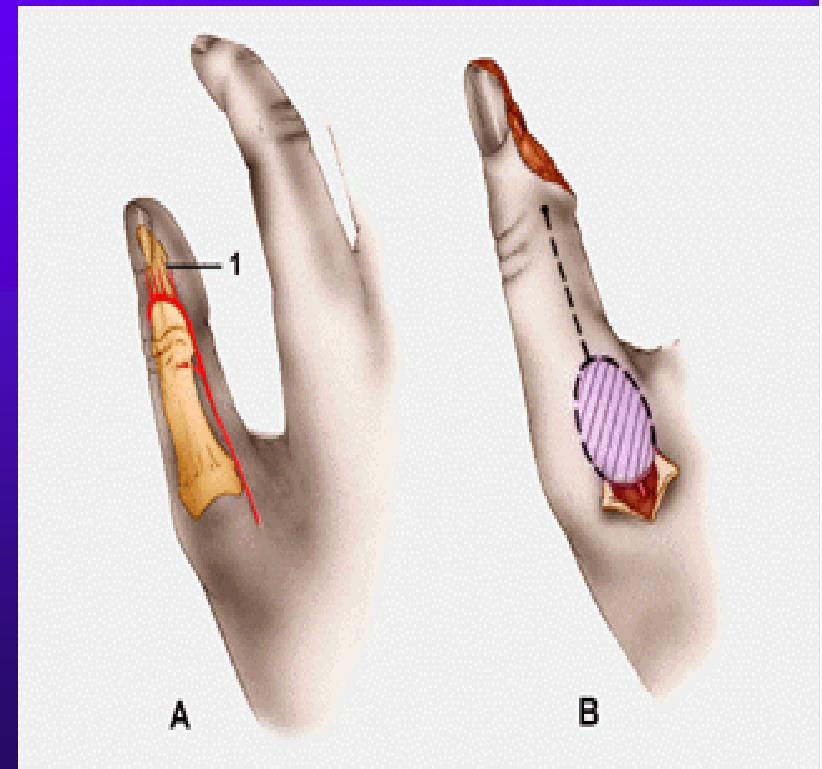
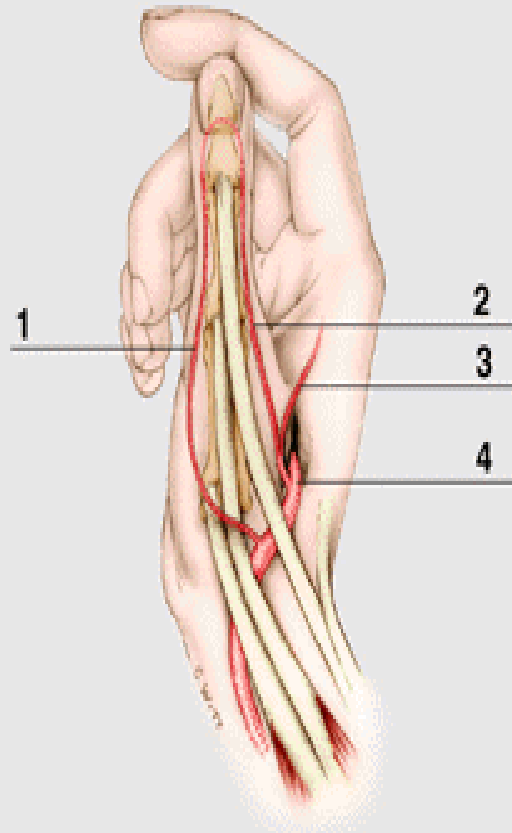


dtto



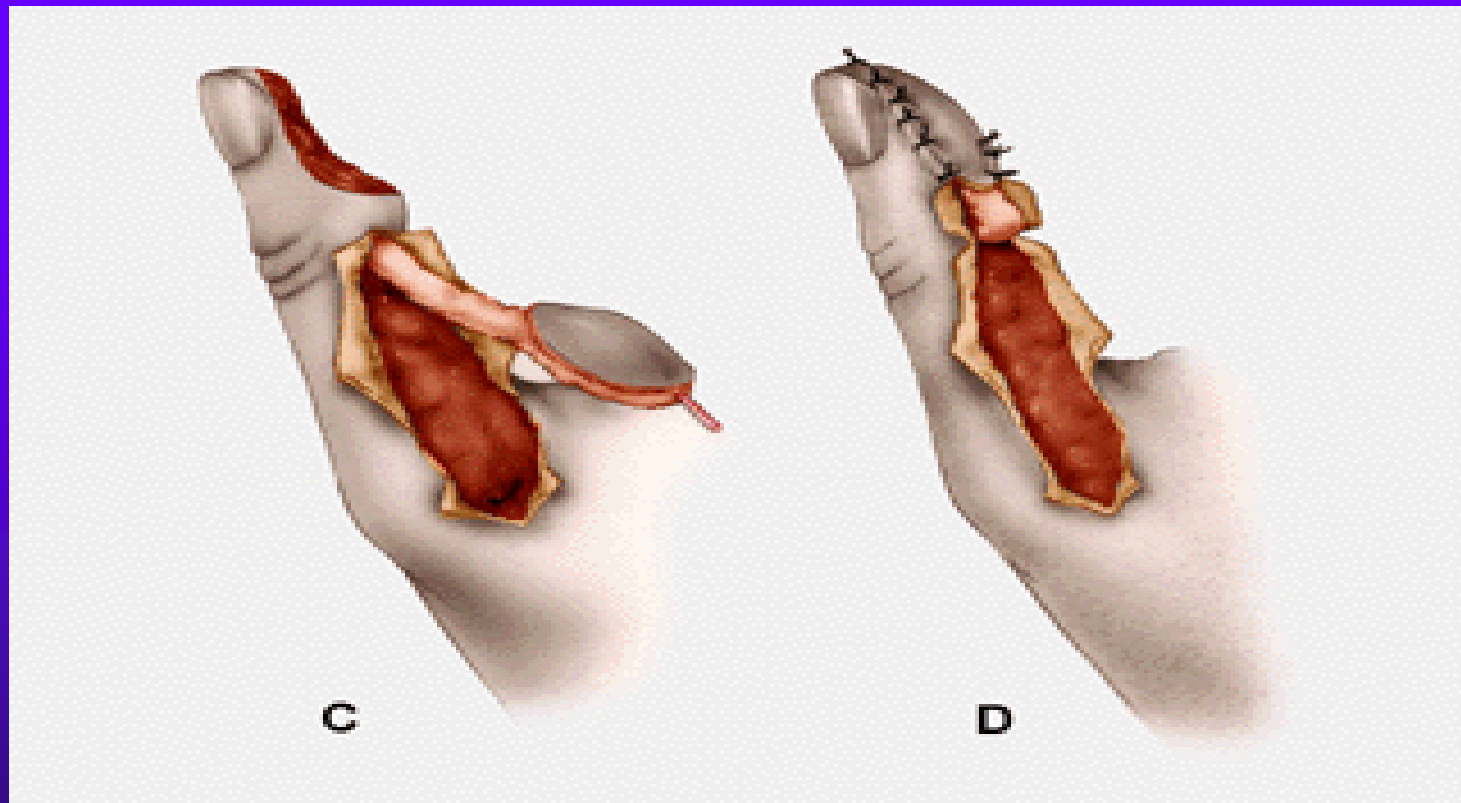
# Homodigitalni dorsoulnarni lalok palce (zalozeny na a.dorsoulnaris=vetev I.dorsalni intermetacarpalni art.)

- ◆ Anastomosa na urovni neht.matrix

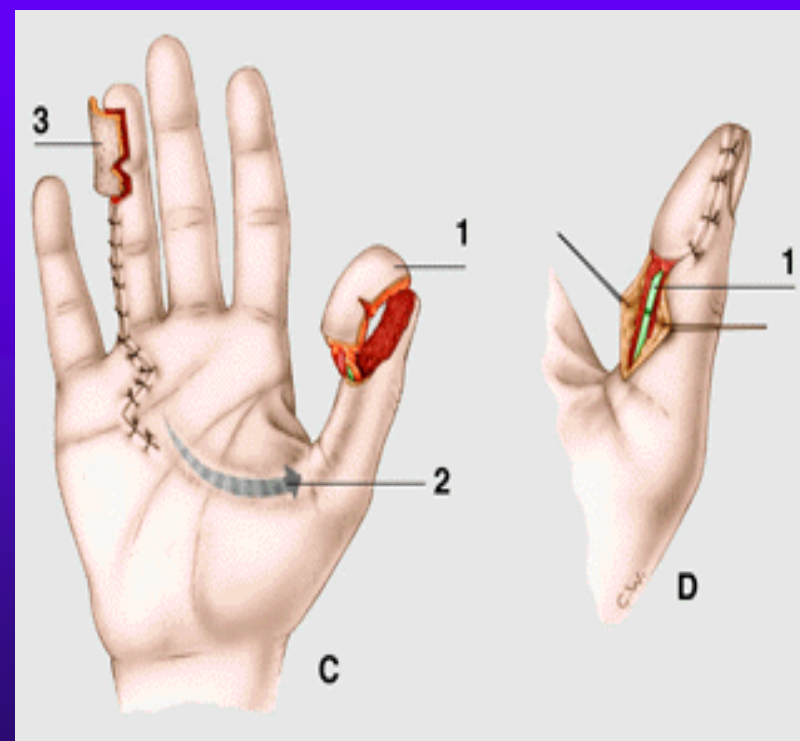
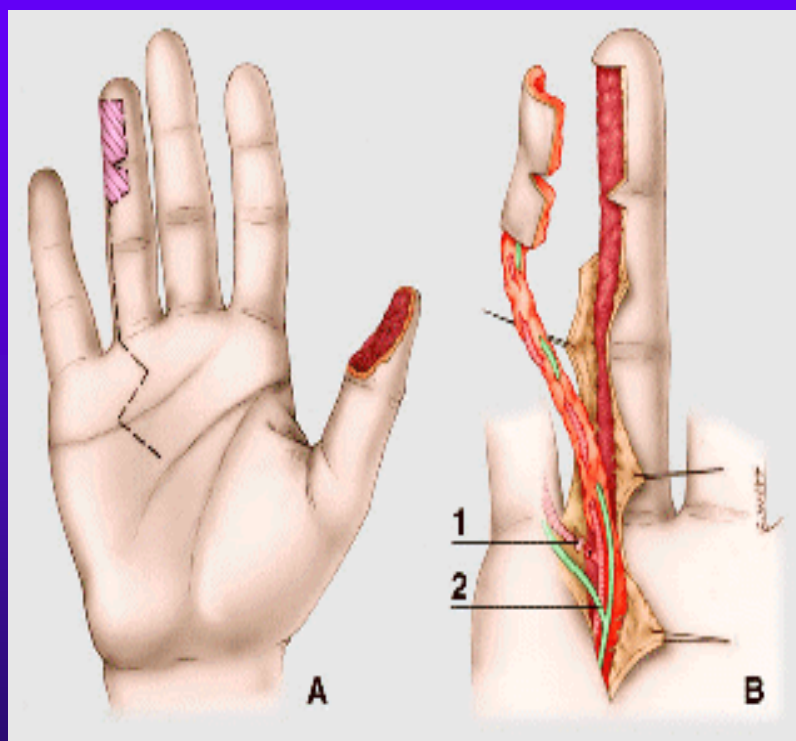




dtto

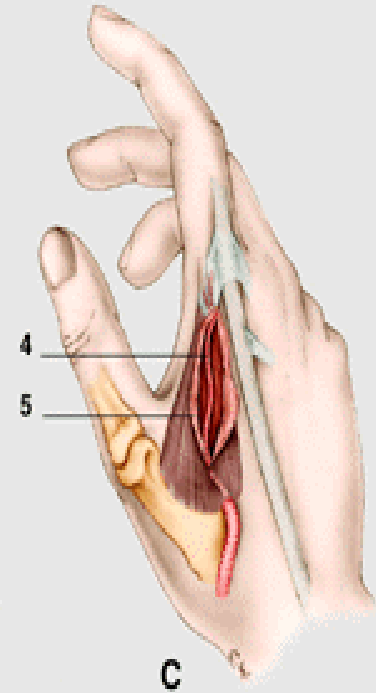
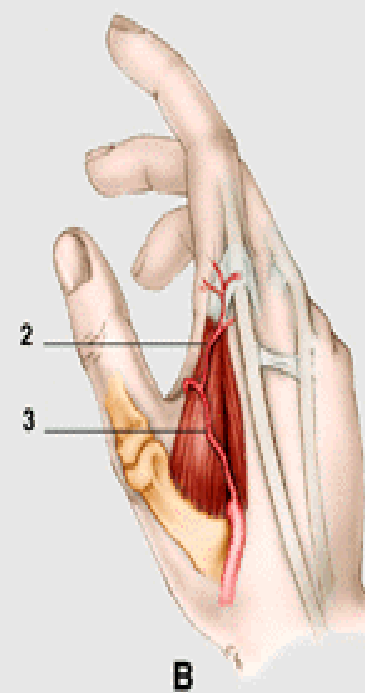
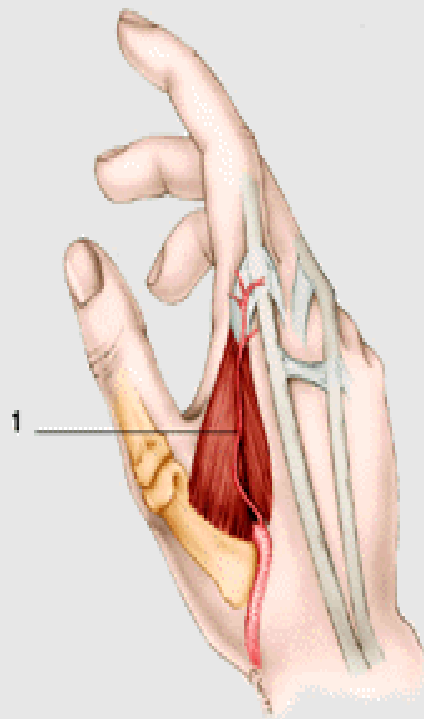


# Heterodigitalni pulparni stopkaty lalok ( Littleruv lalok)



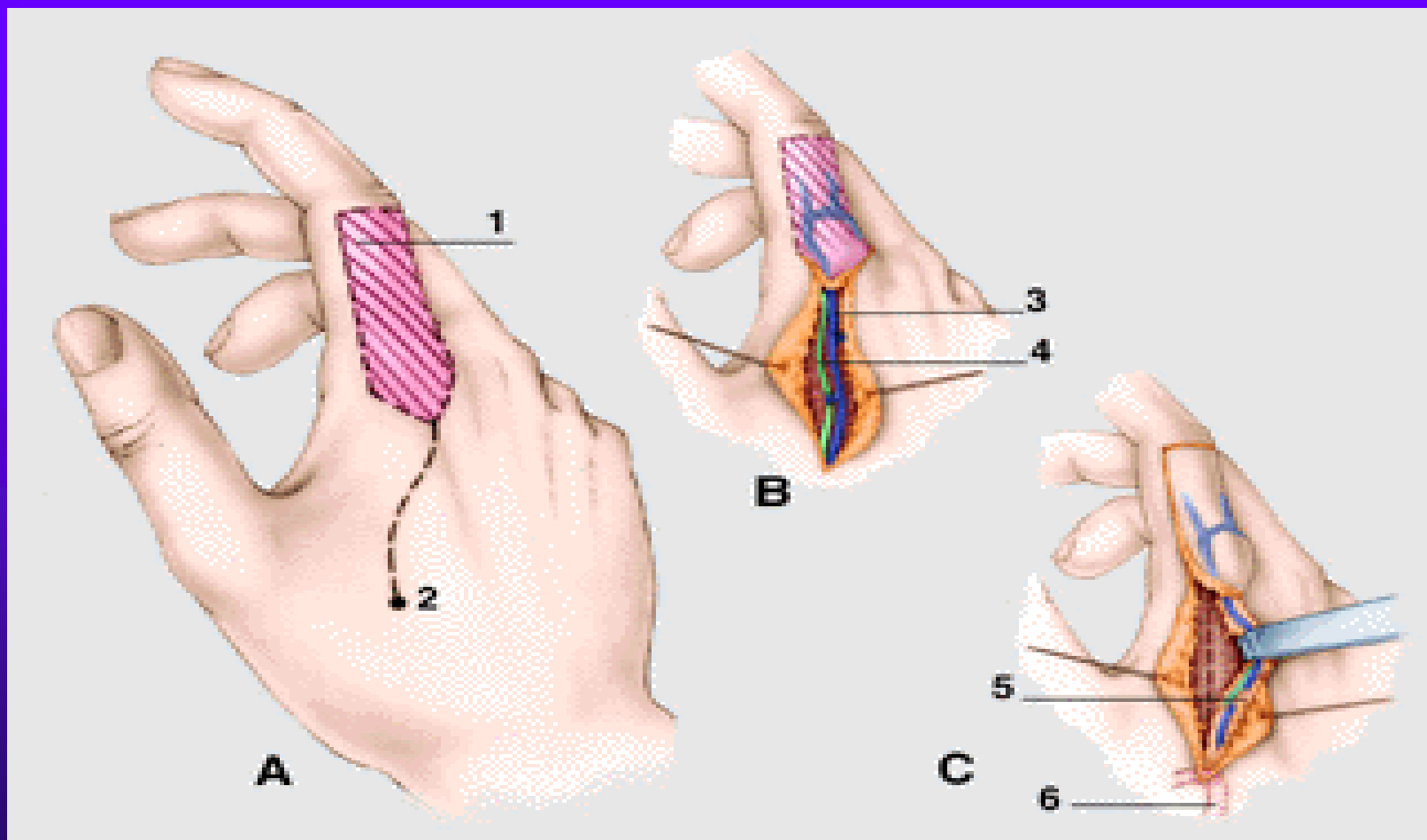


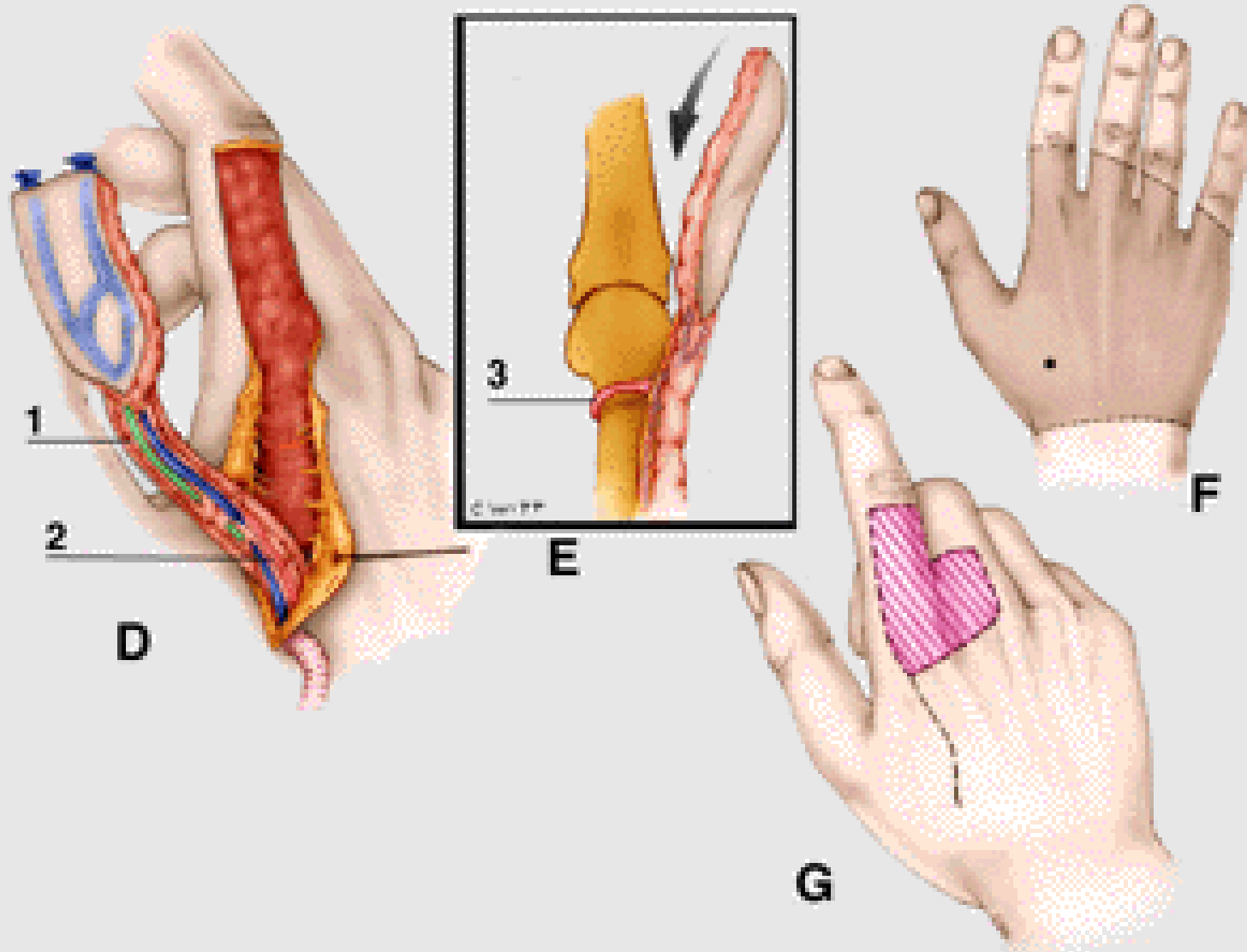
# Lalok « drak »



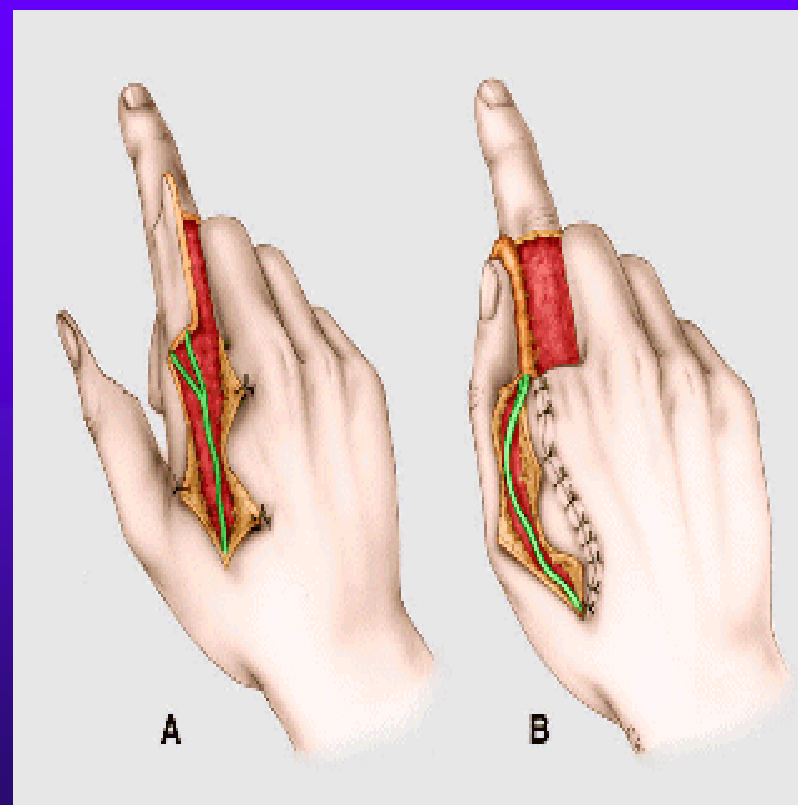
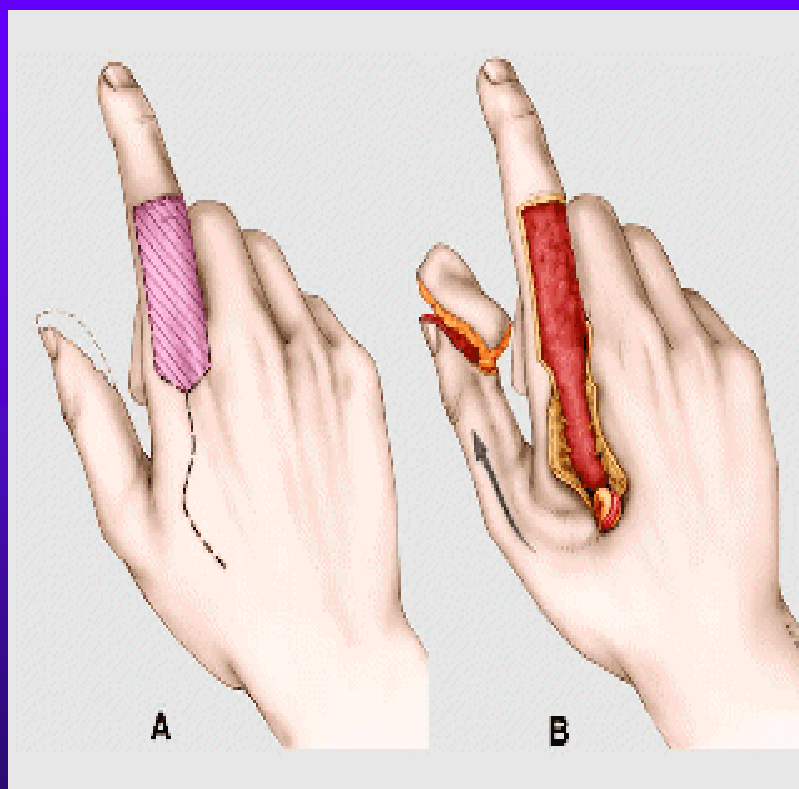


# Technika dissekce

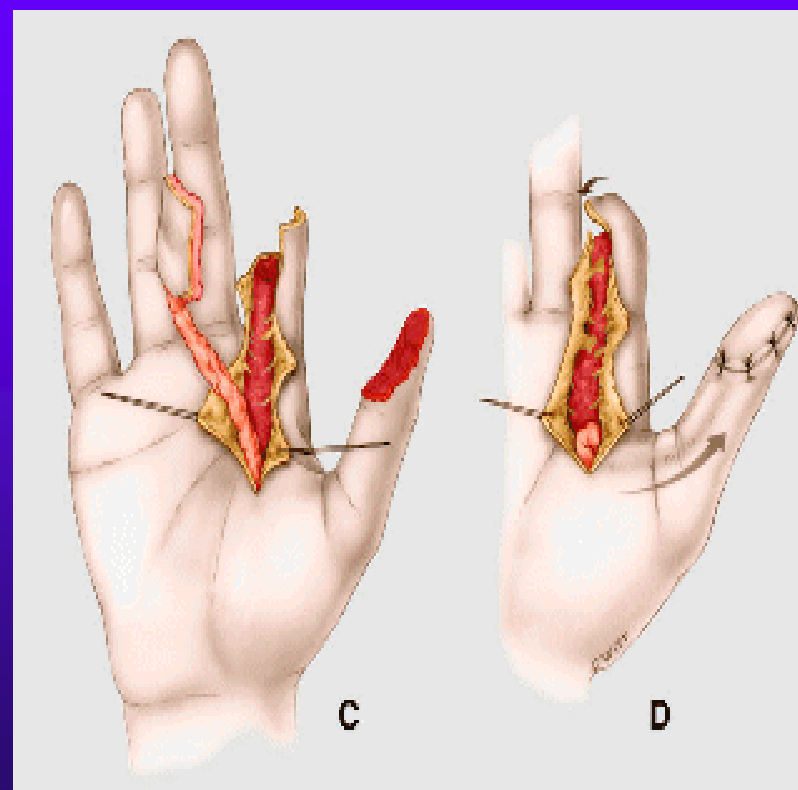
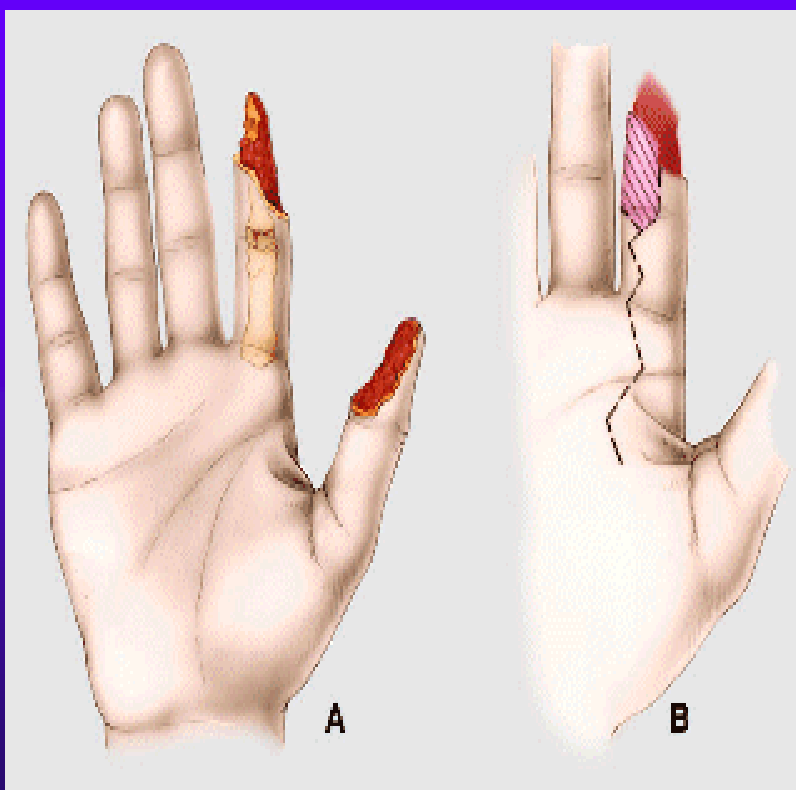




# Lalok « drak » pro pulparni ztratu palce

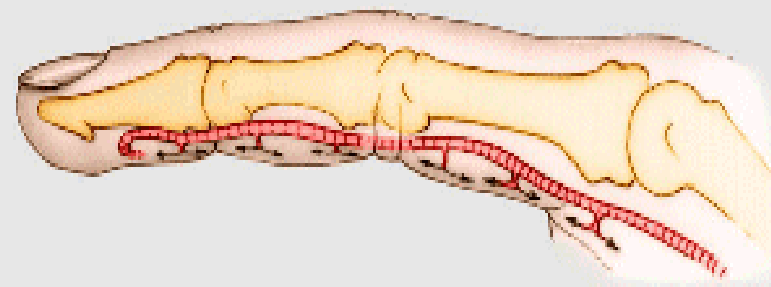
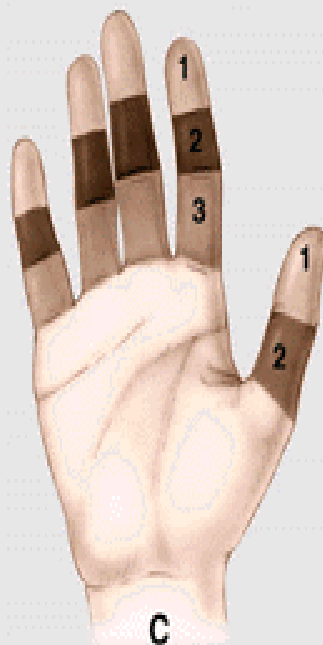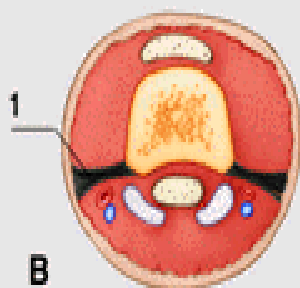
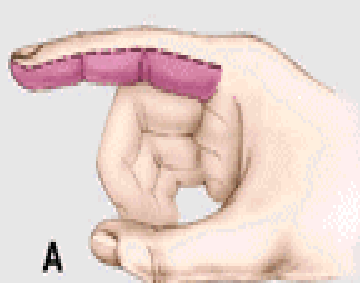


# Heterodigitalni stopkaty lalok z prstu « banky » urcеноho k amputaci

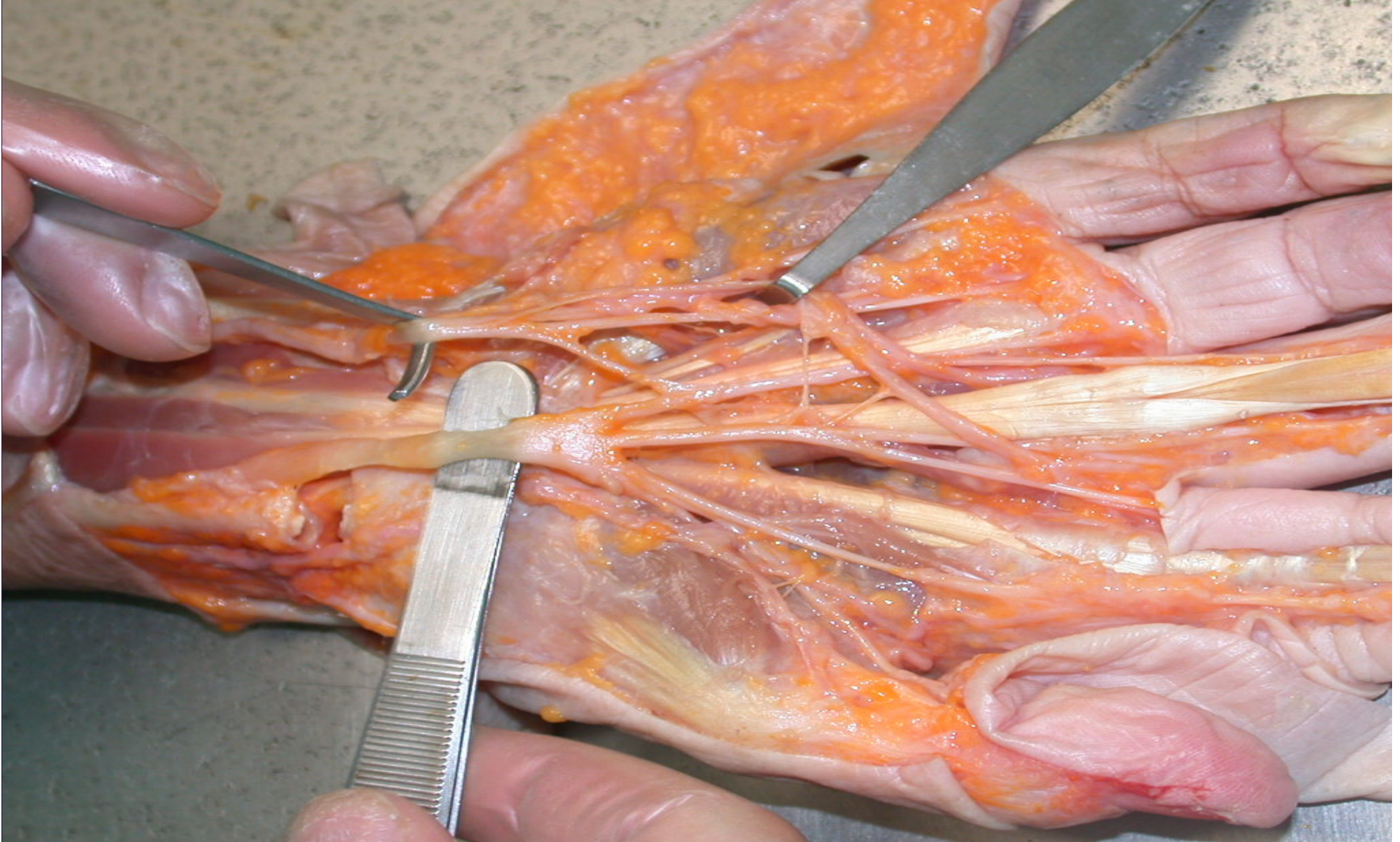

# Ztraty kozniho krytu stredniho segmentu prstu

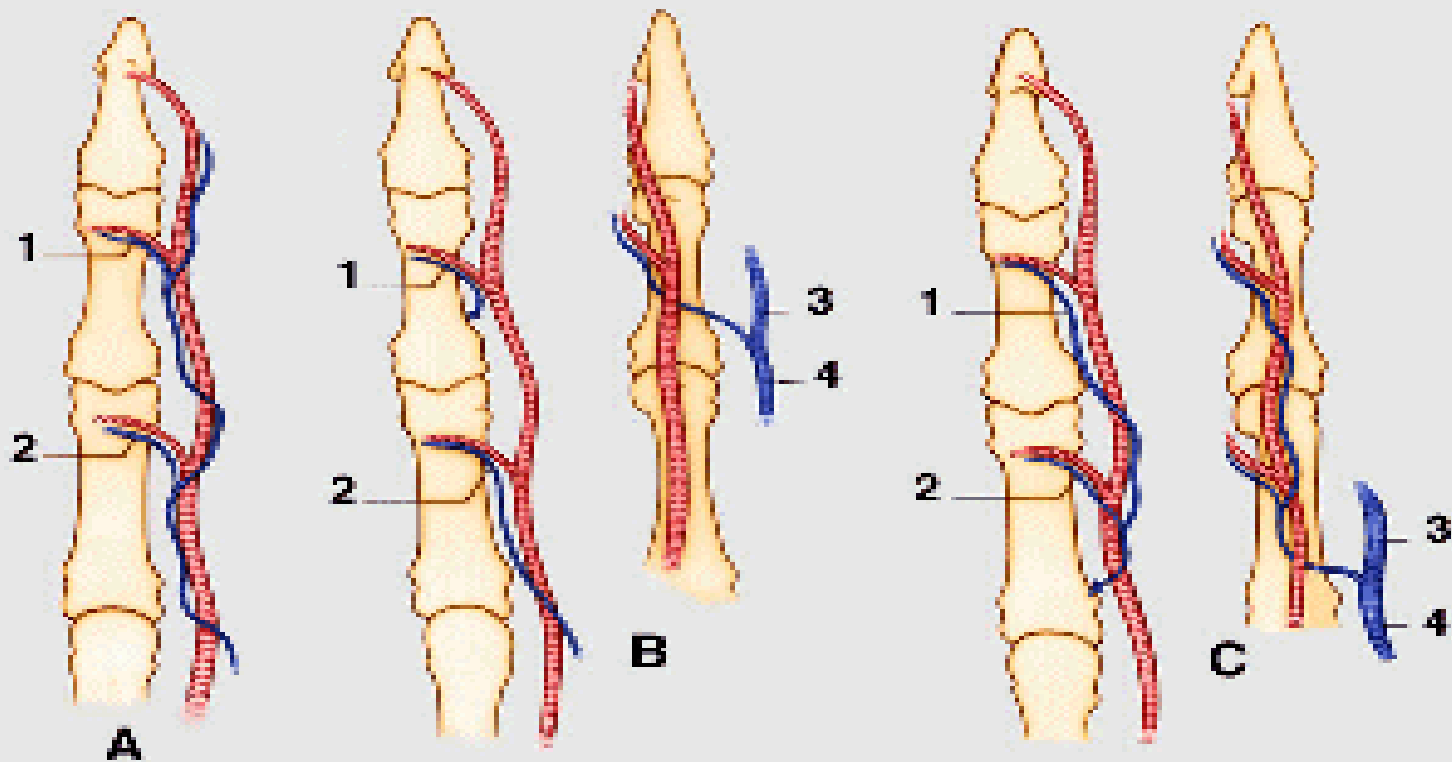
◆ Anatomie



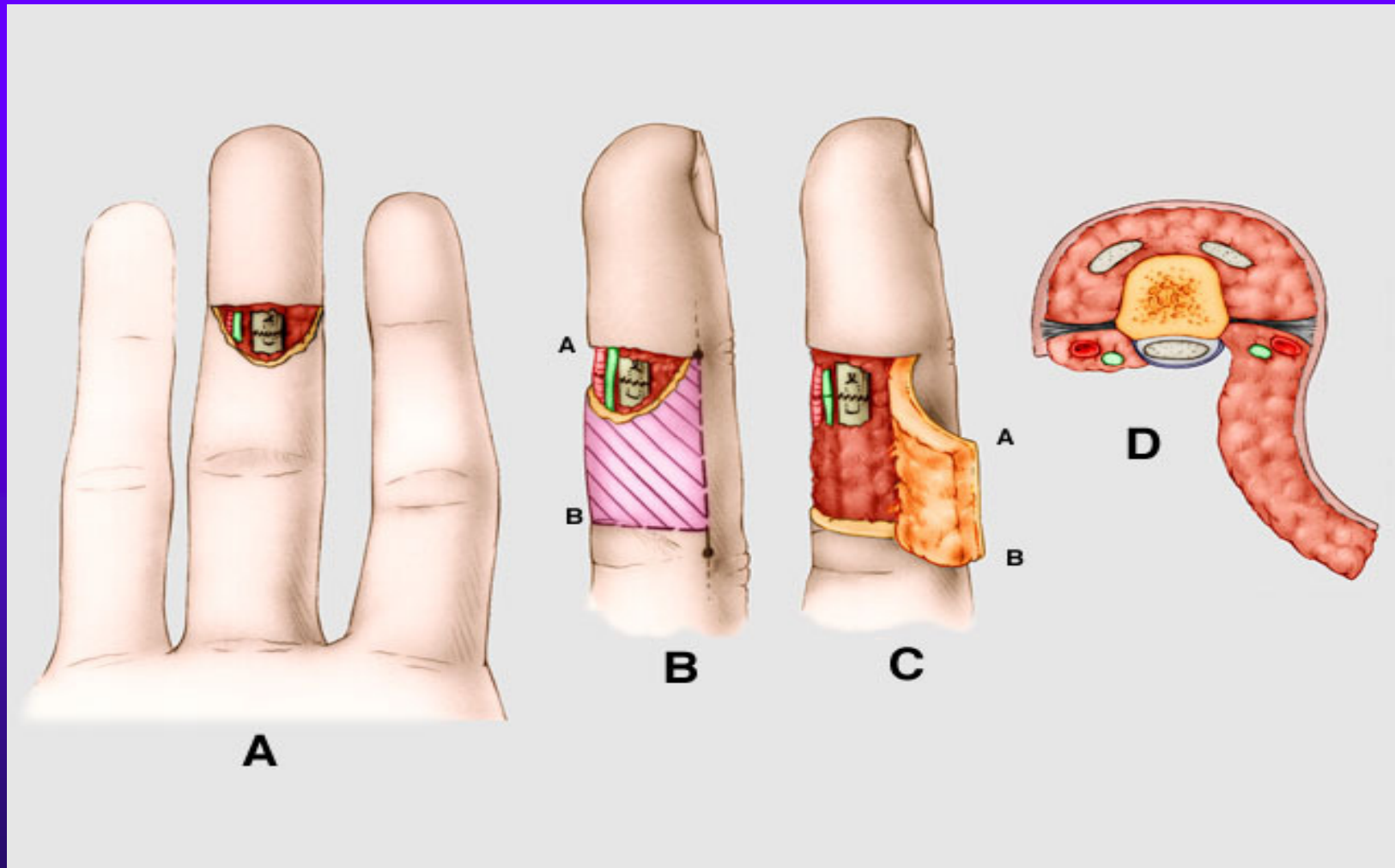




# Anastomosisy na urovni krcku phalangu



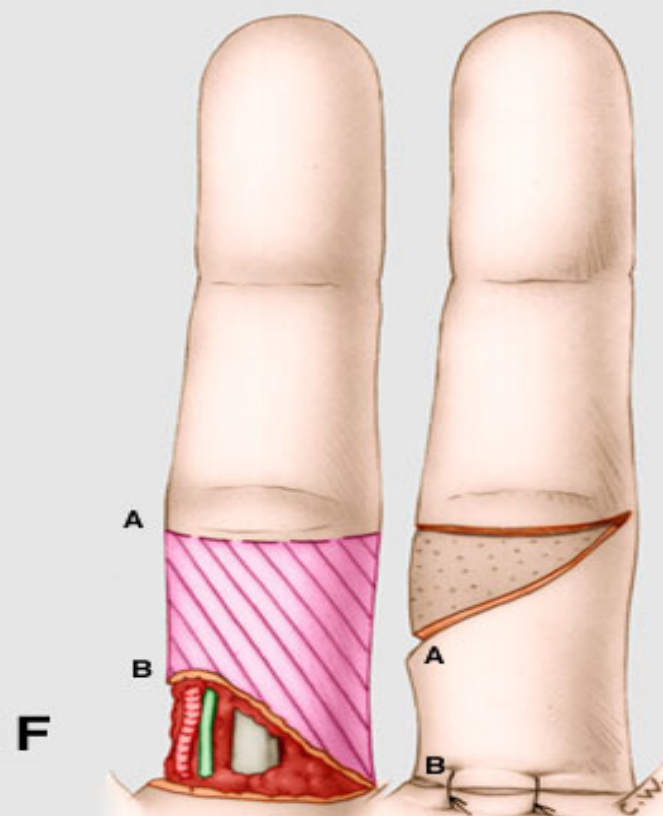
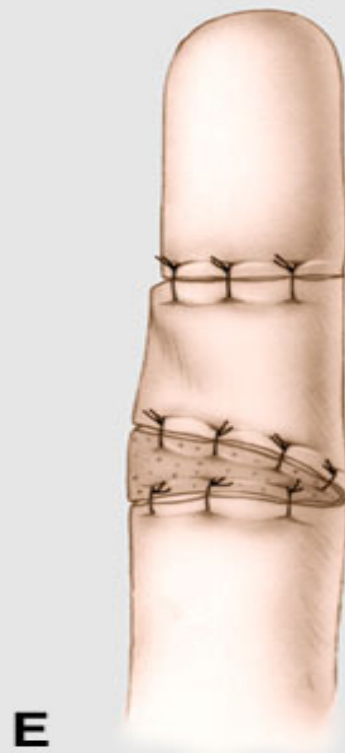# Huestonuv lalok



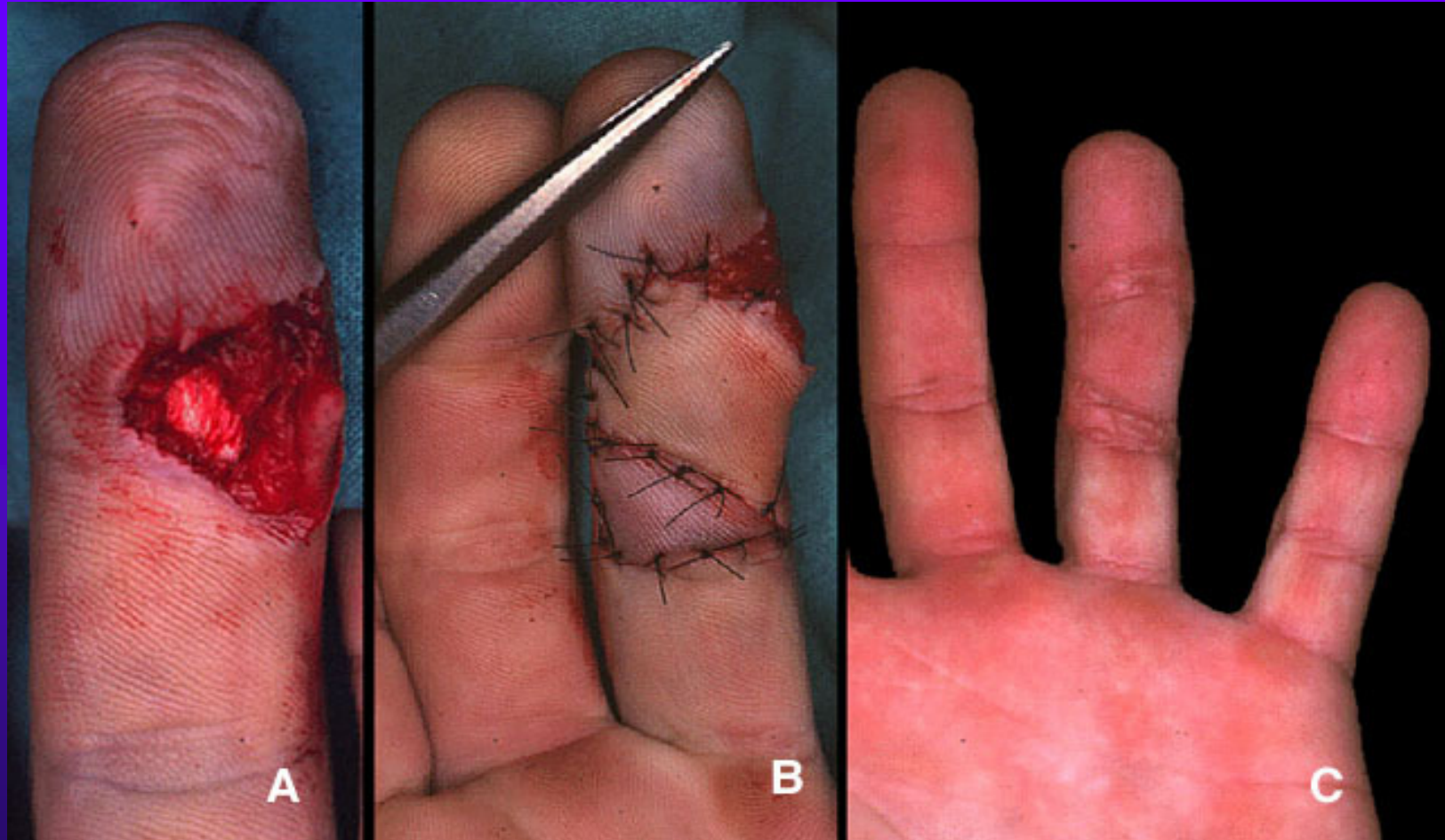




dtto

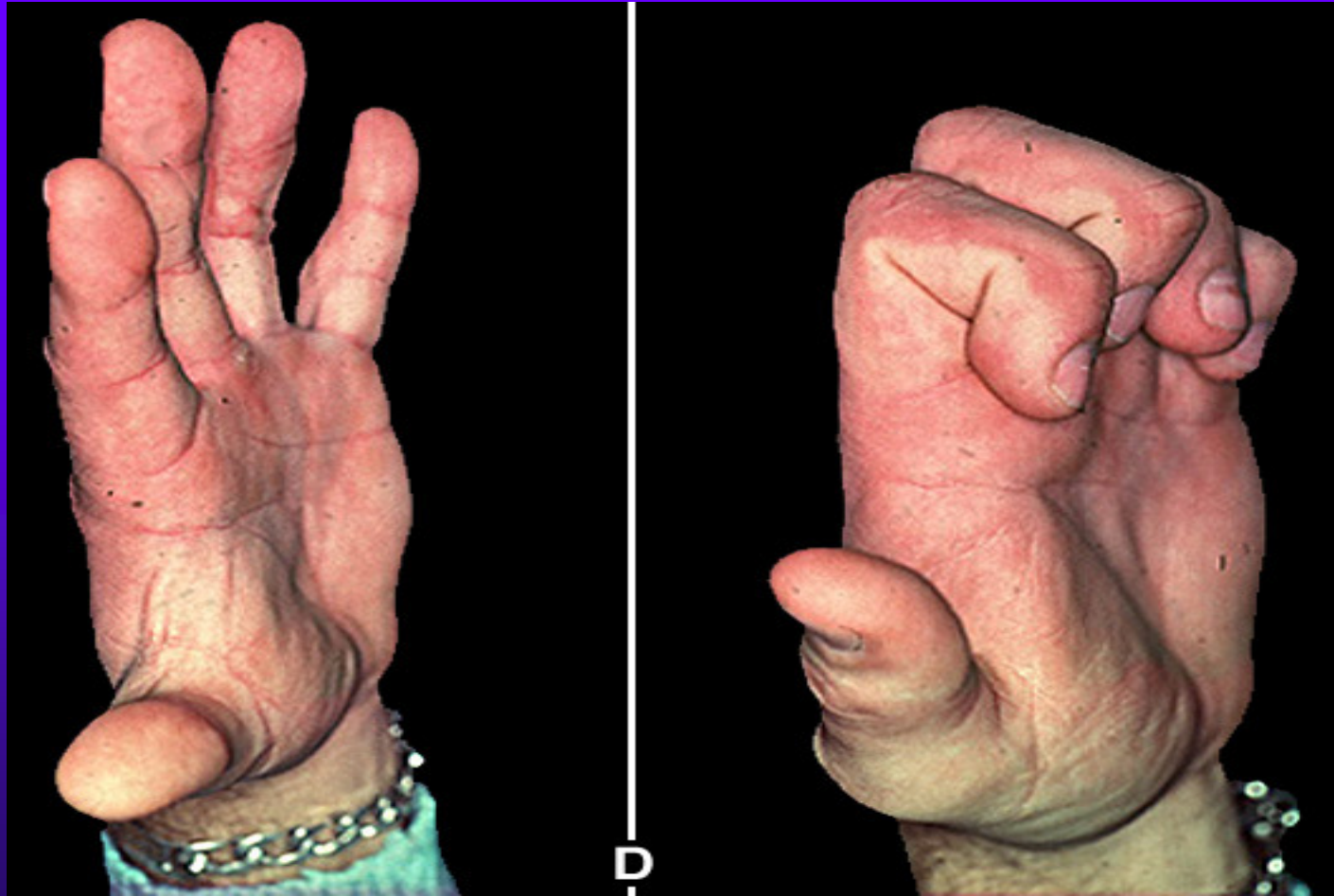


# Huestonuv lalok



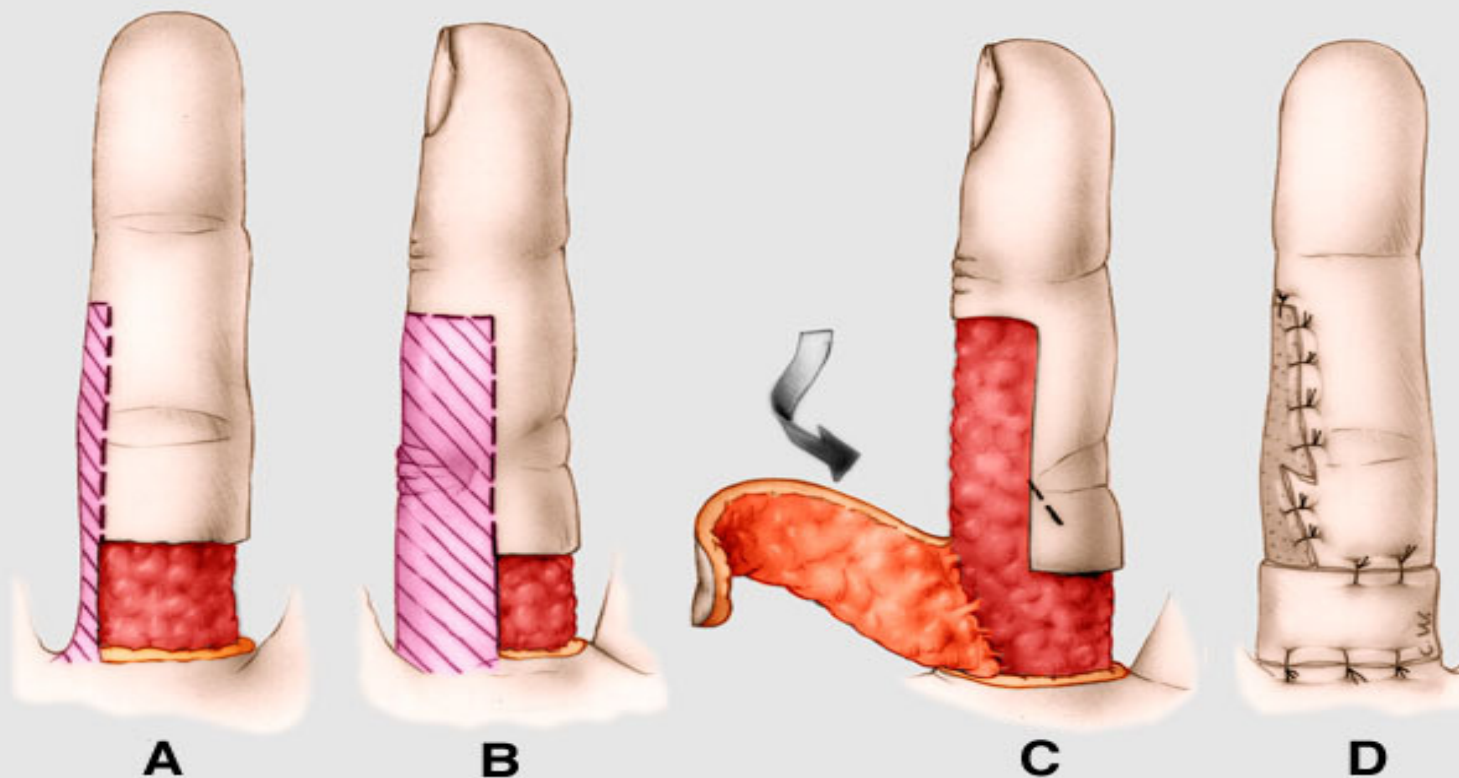


dtto

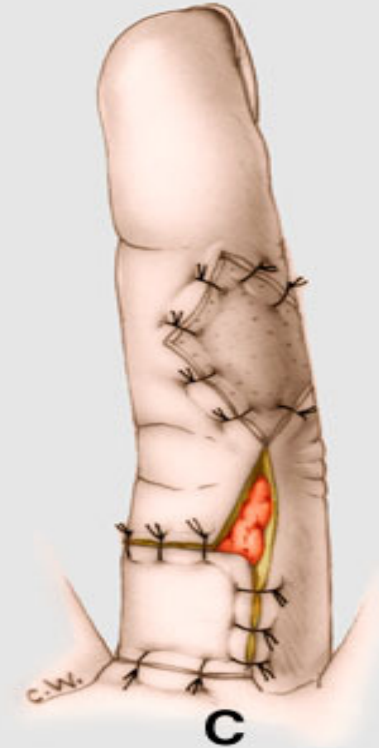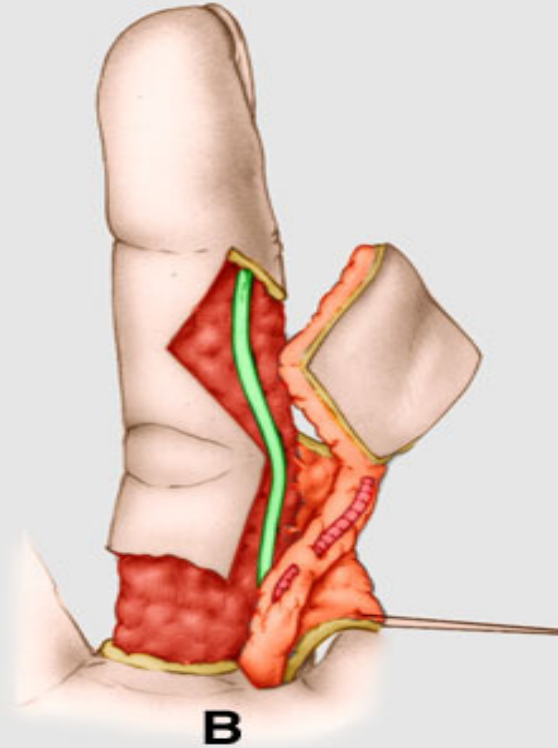
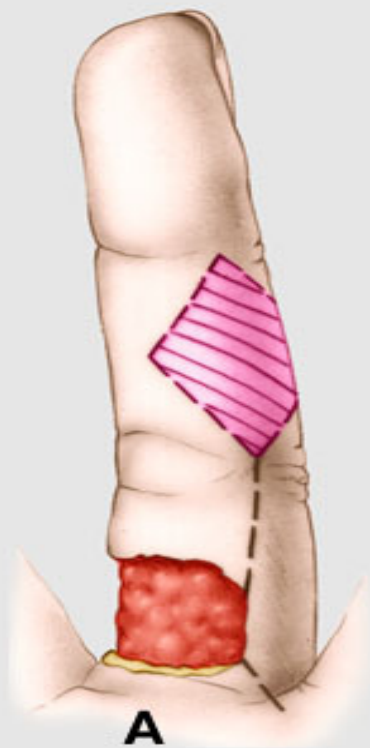




# Laterodigitalni lalok

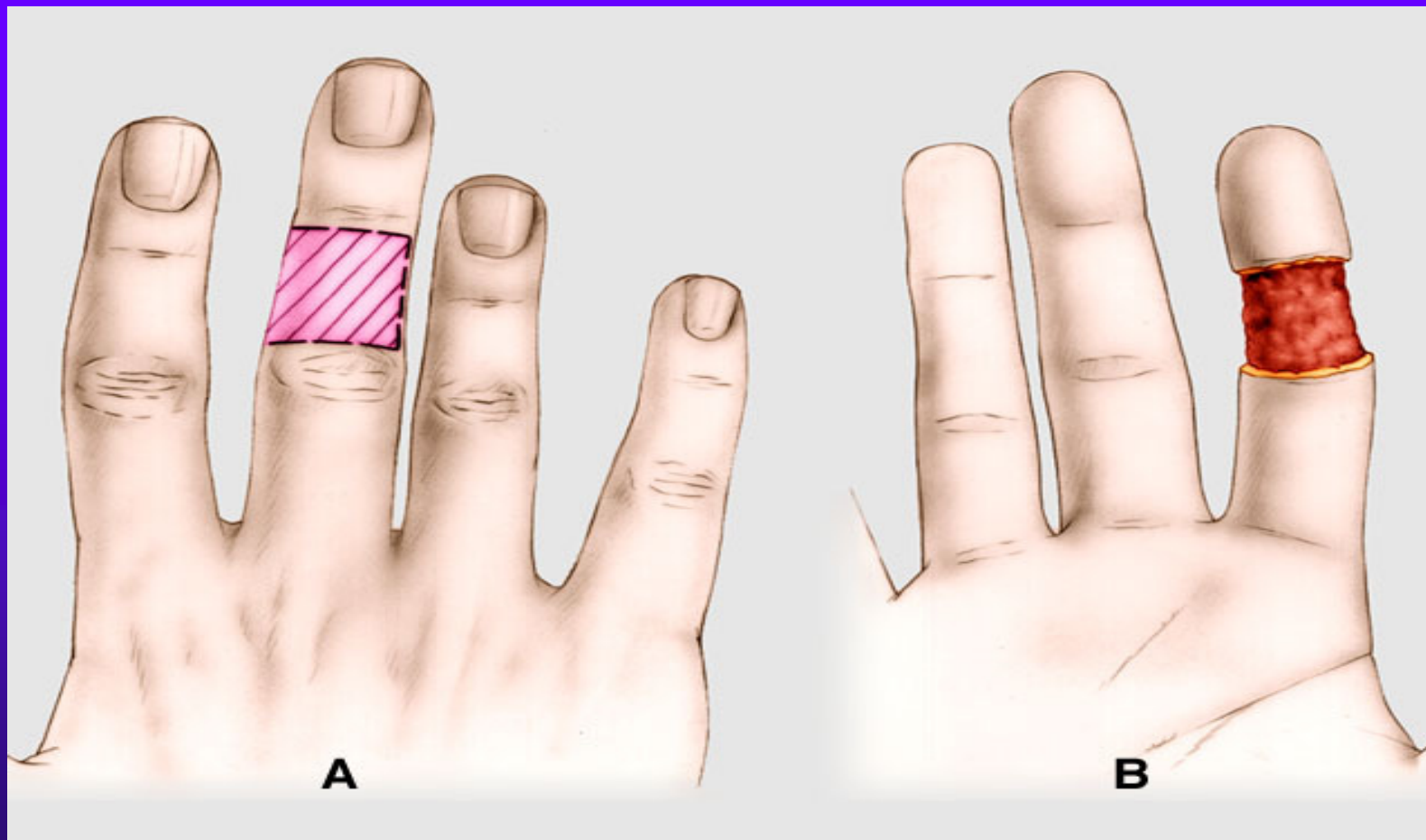


# Stopkaty lalok art.colater.digiti



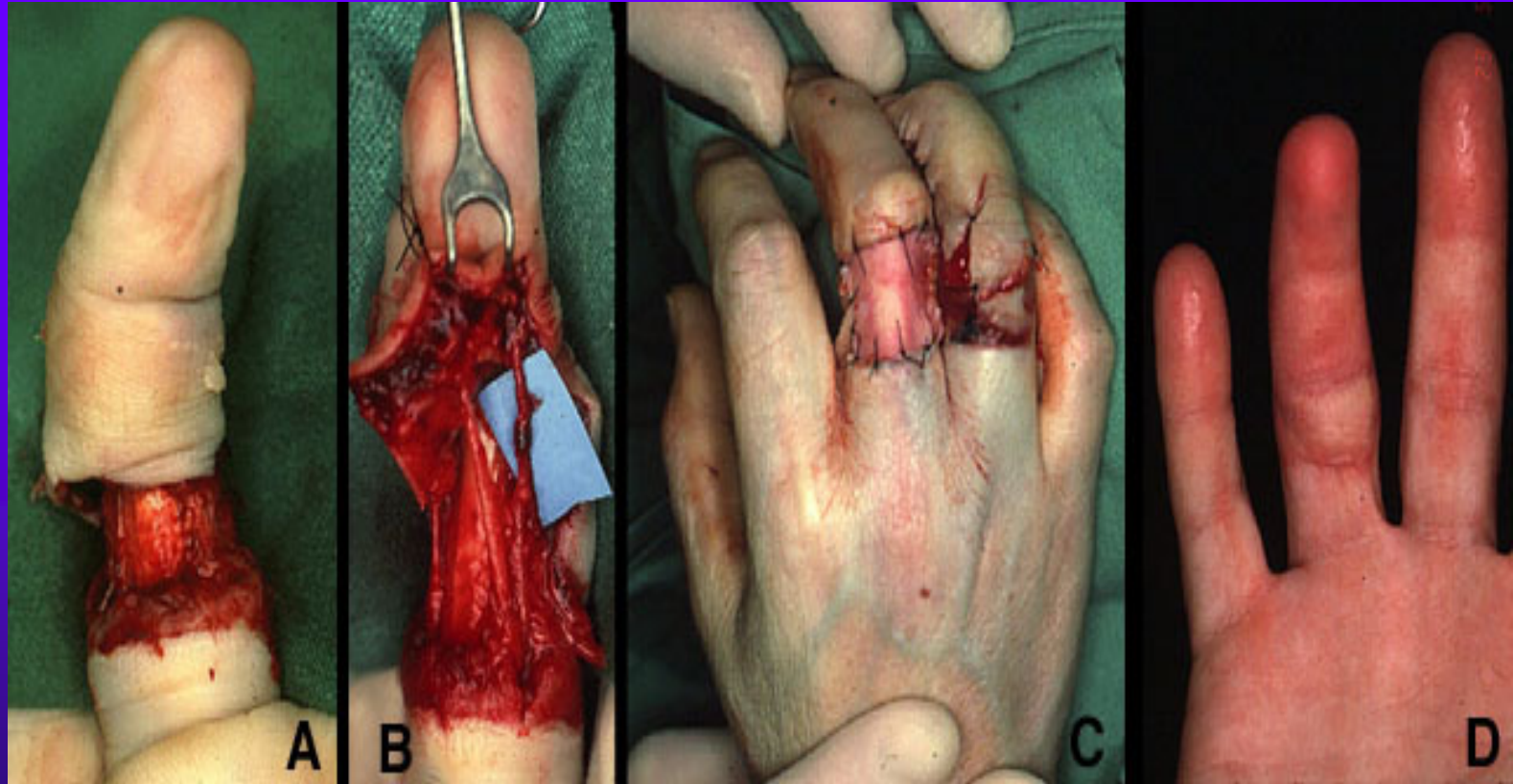


# Cross finger



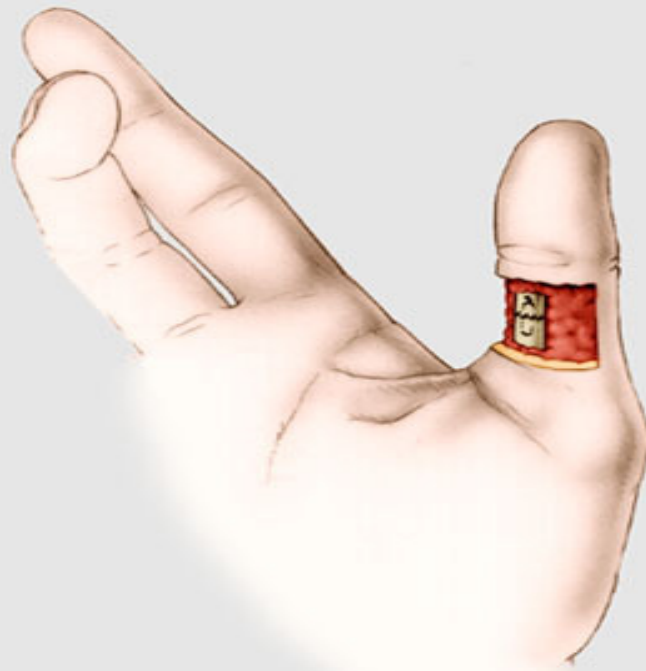


# Cross finger

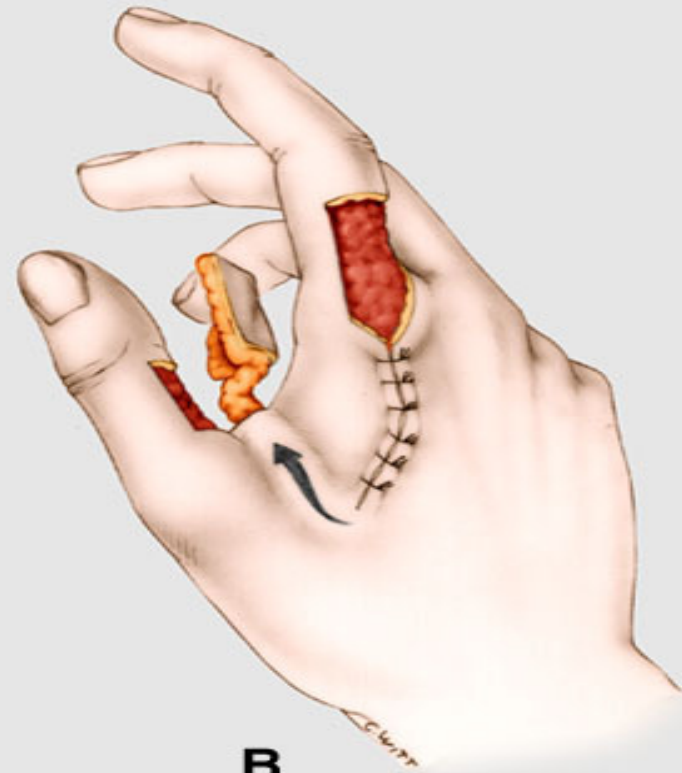




# Lalok « cerf volant » pro str.segment palce



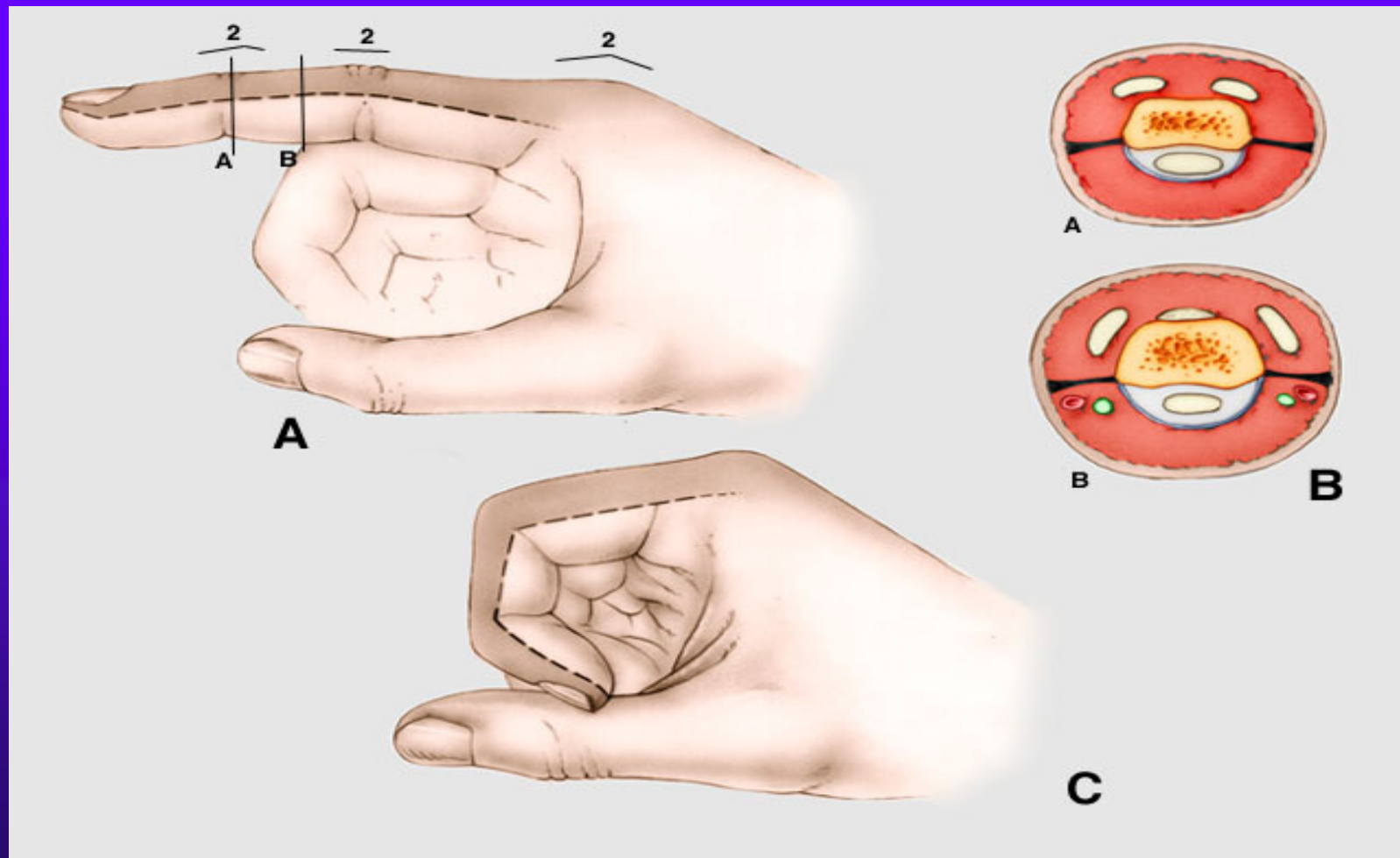
**A**



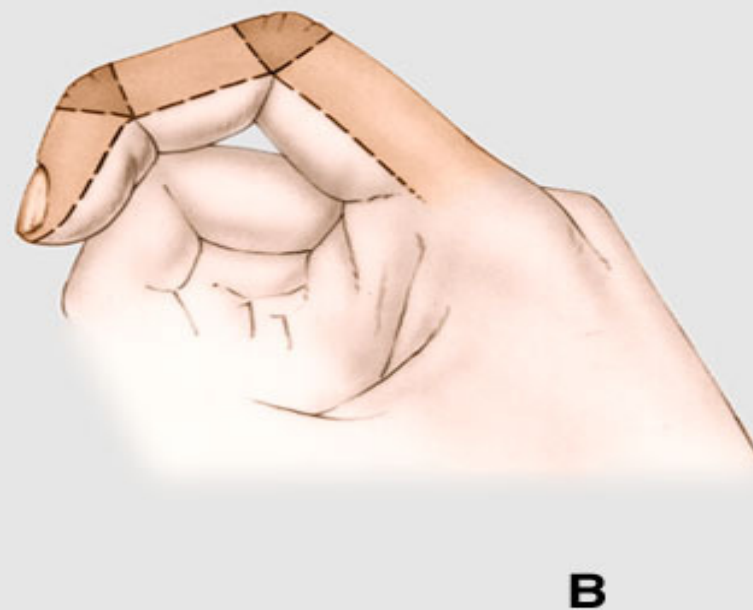
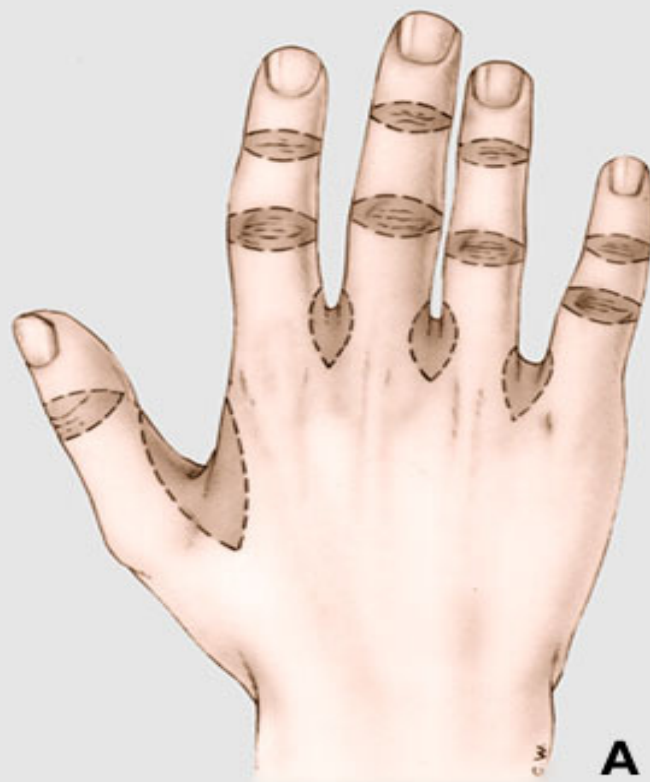**B**



# Dorsalni ztraty kozniho krytu

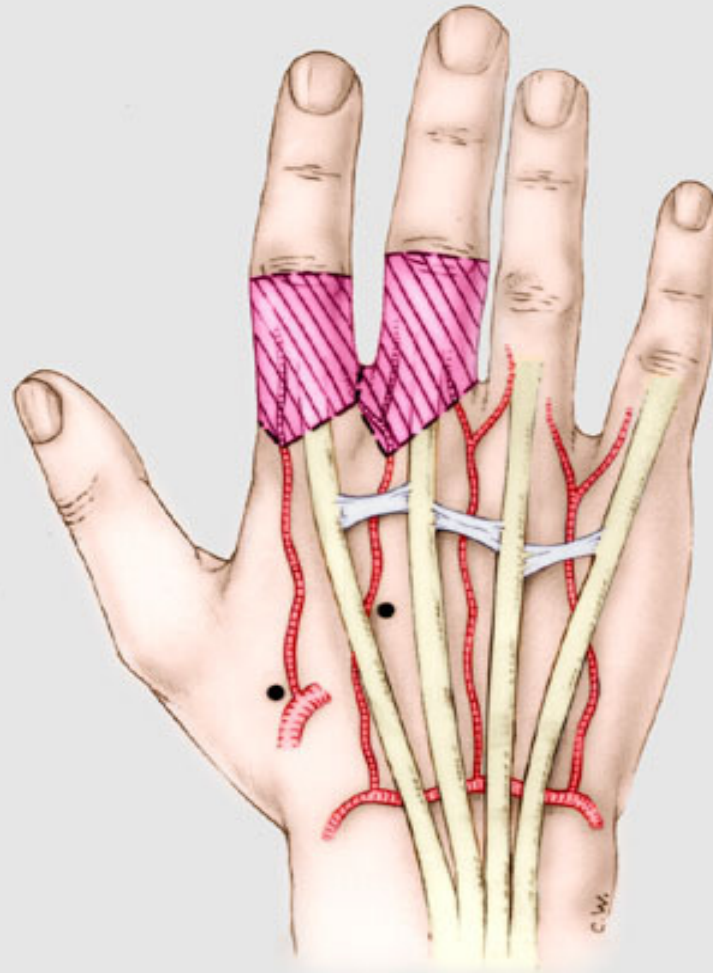


# Funkcni jednotky dors.kozniho krytu

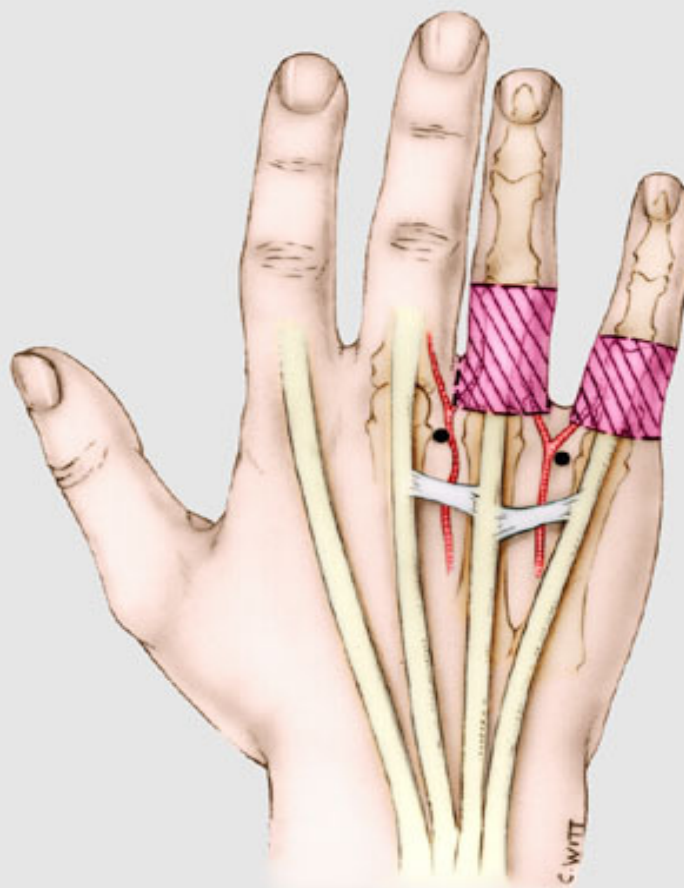




# Vascularizace 1 a 2-ho intermetacarp.prostororu

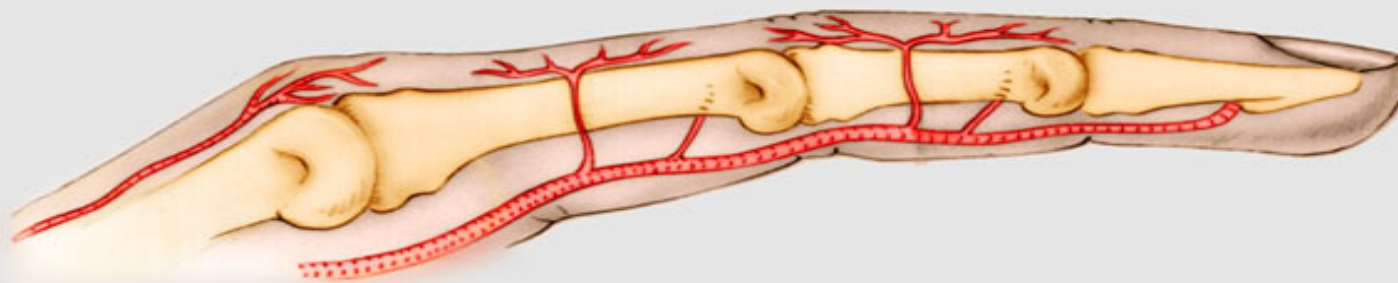


# Vascularizace 3 a 4-teho internet.prostoru

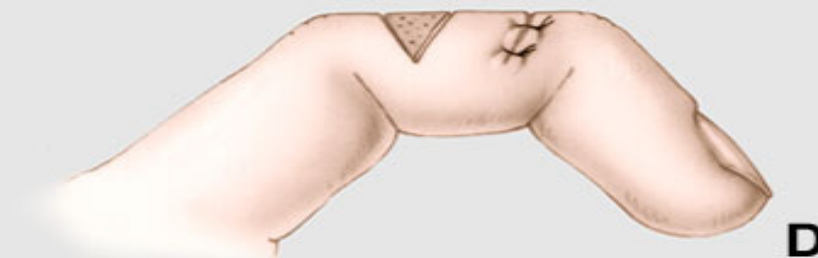
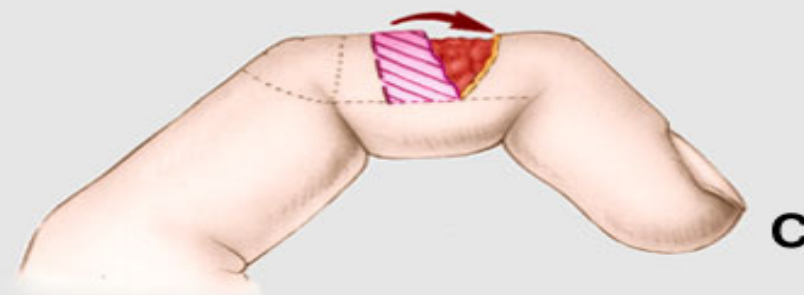
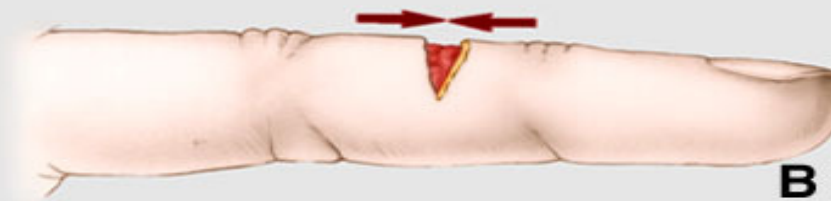
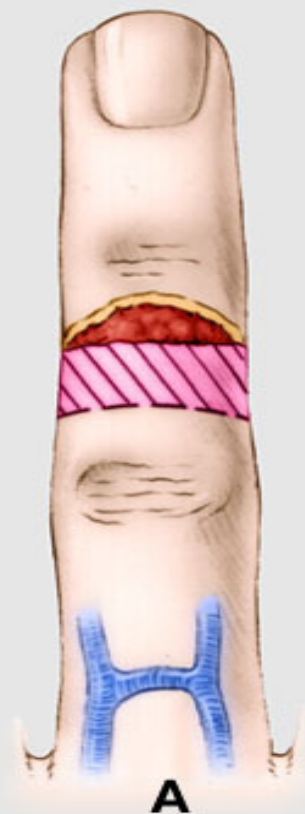


# Participace colater.arterii na vascularizaci dorsa prstu

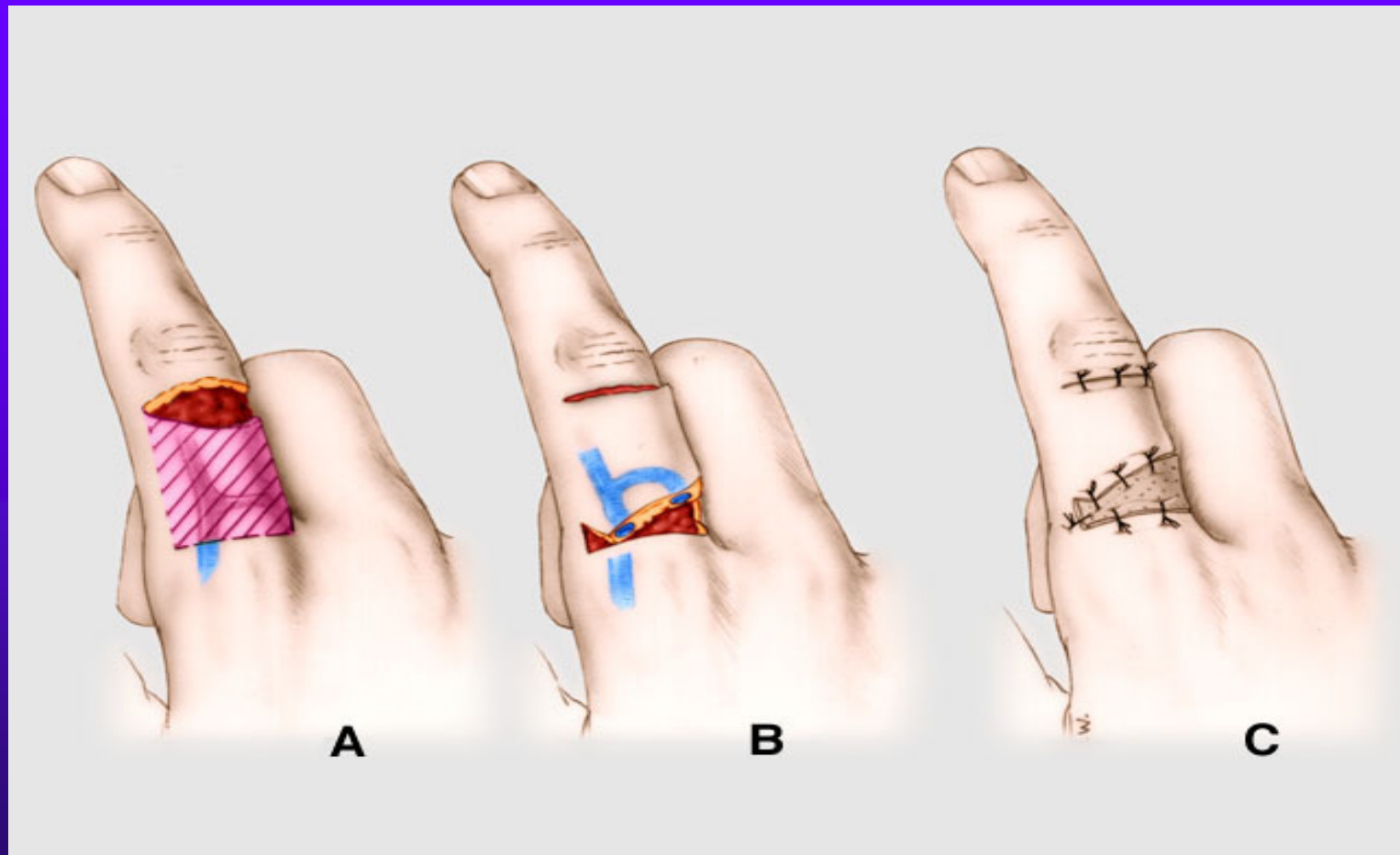

# Dvoustopkatý posuvný lalok

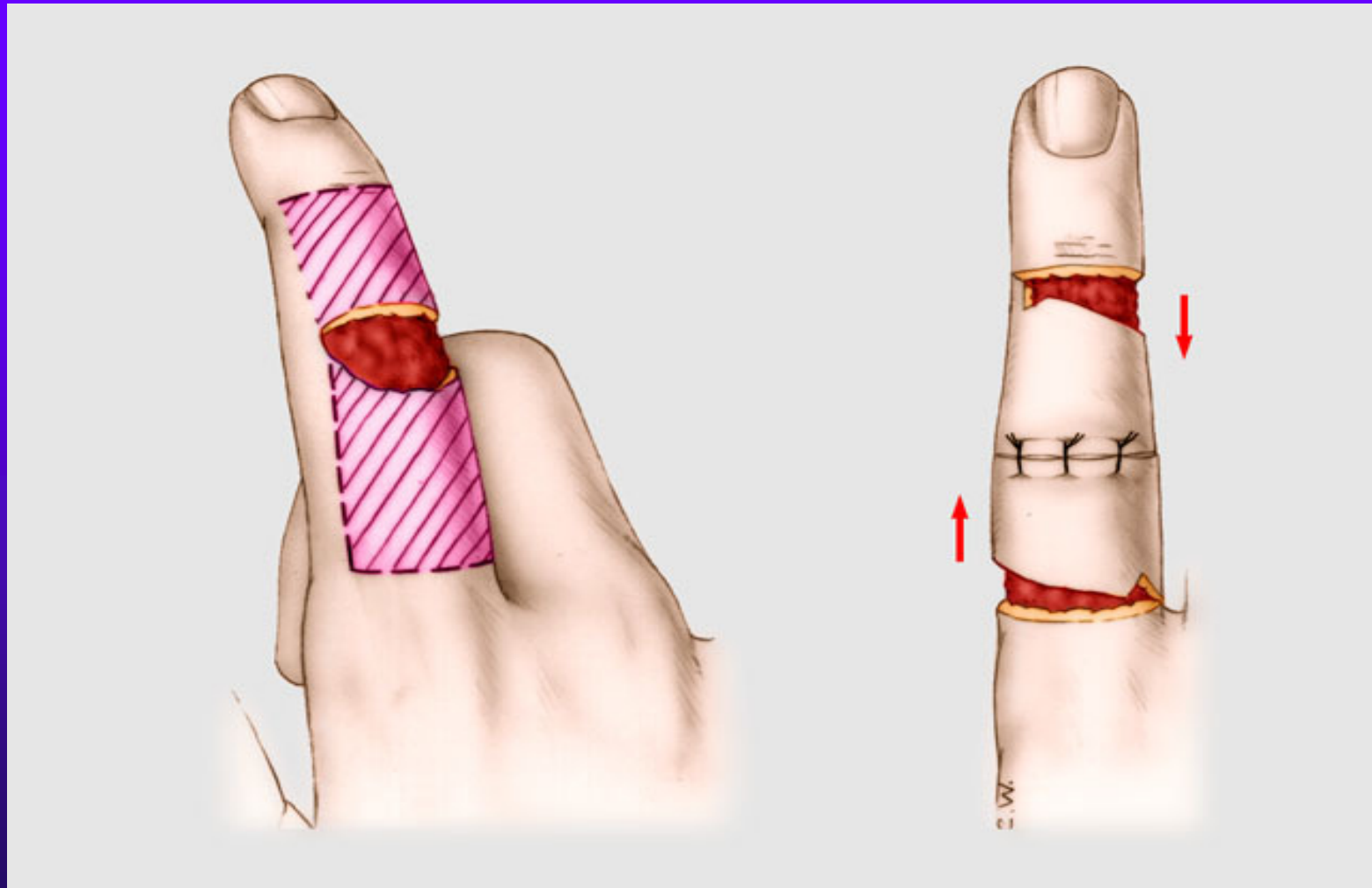




# Lalok zvany dorsalni Hueston

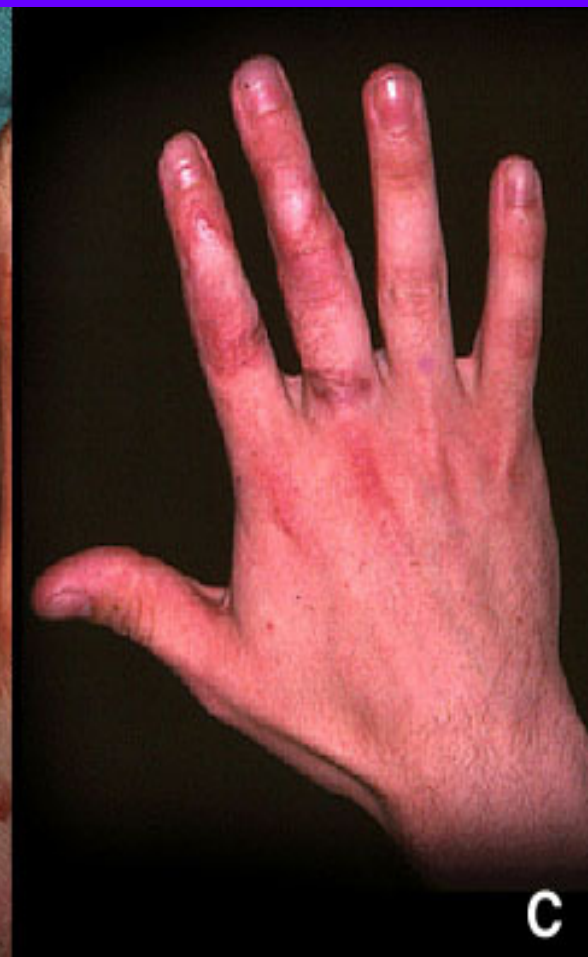
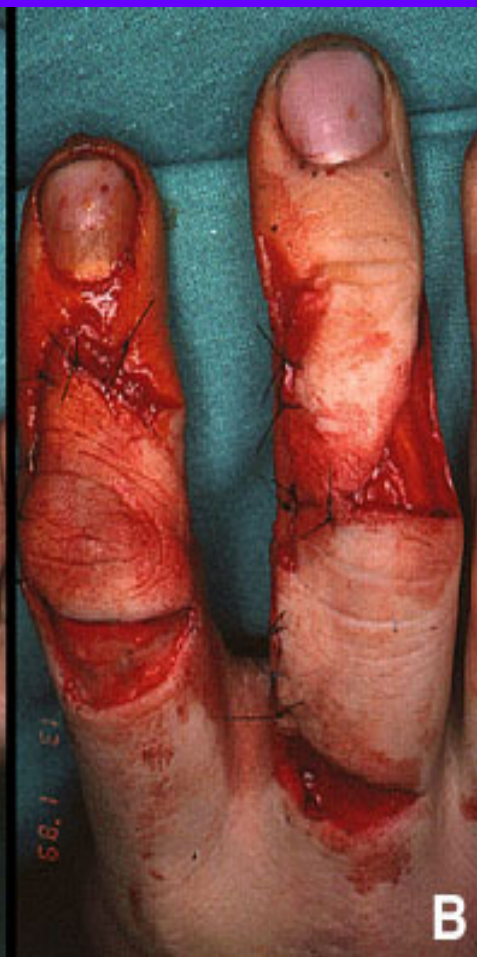
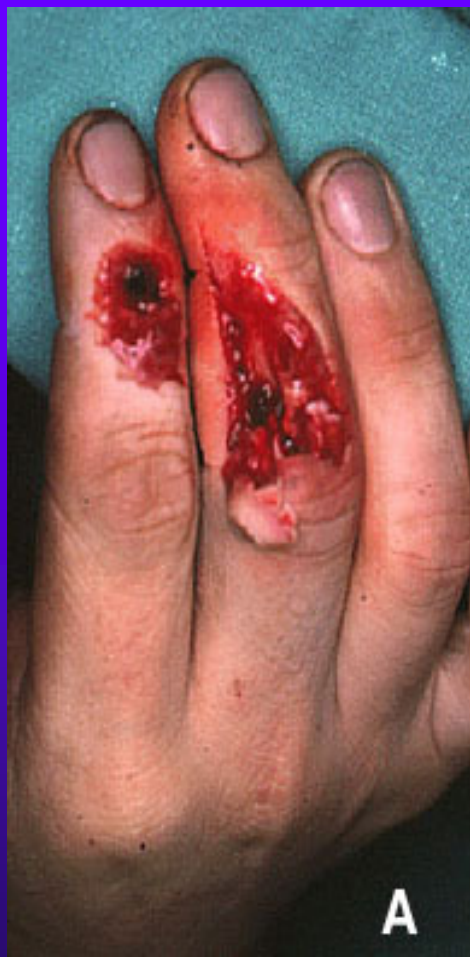# Dvojity dorsalni Huestonuv lalok

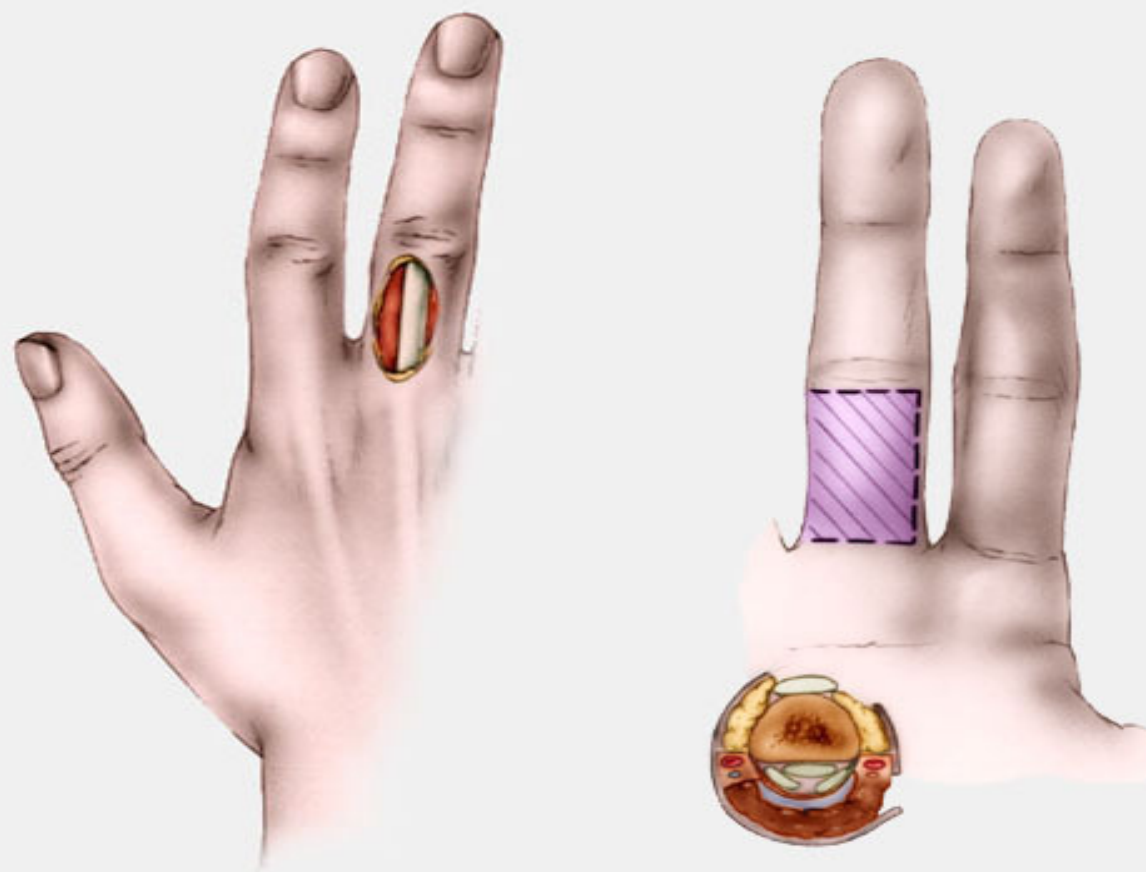




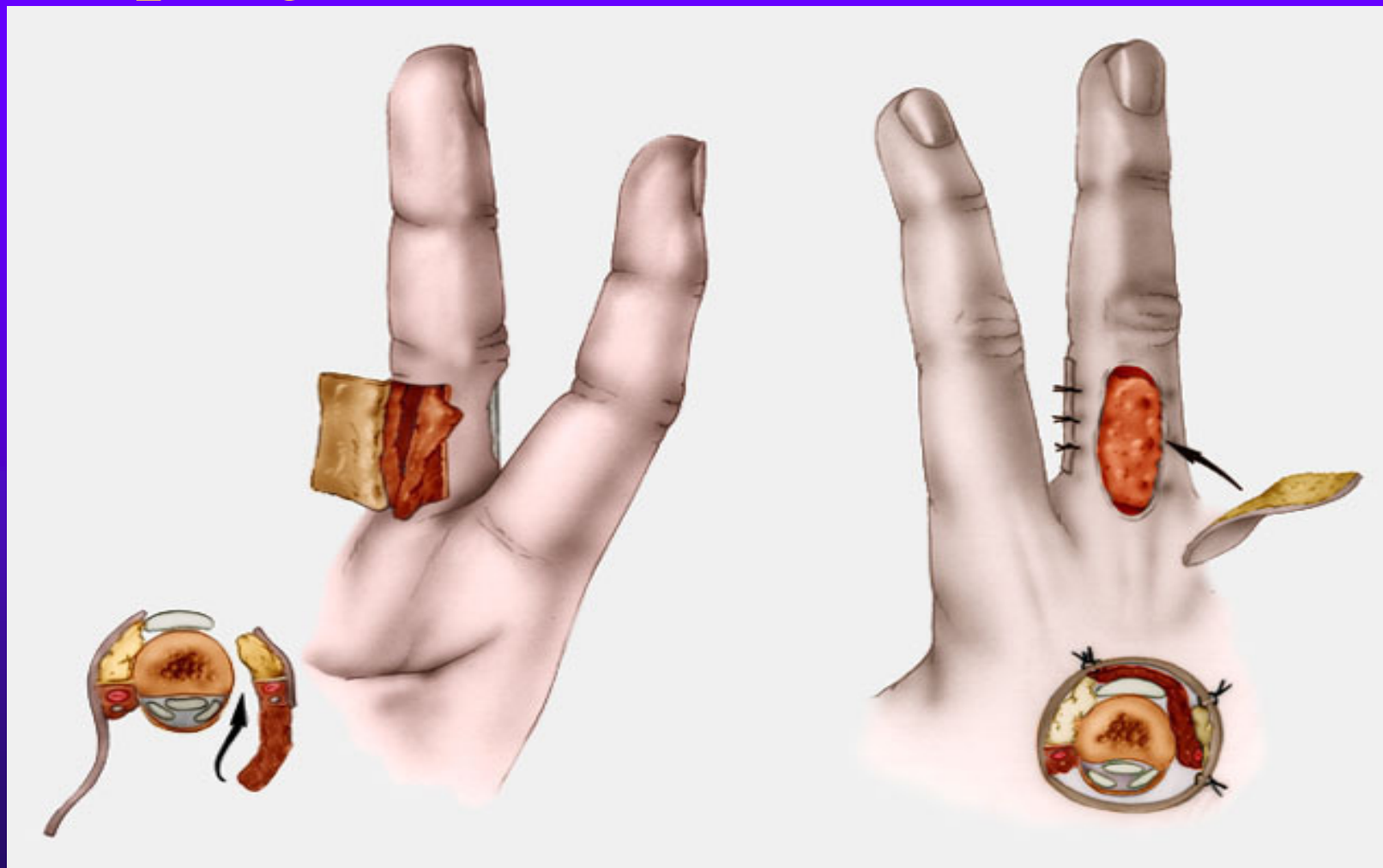# L.Hueston & obdelnikovy rotacni lalok



# Desepidermizovany homodigitalni lalok

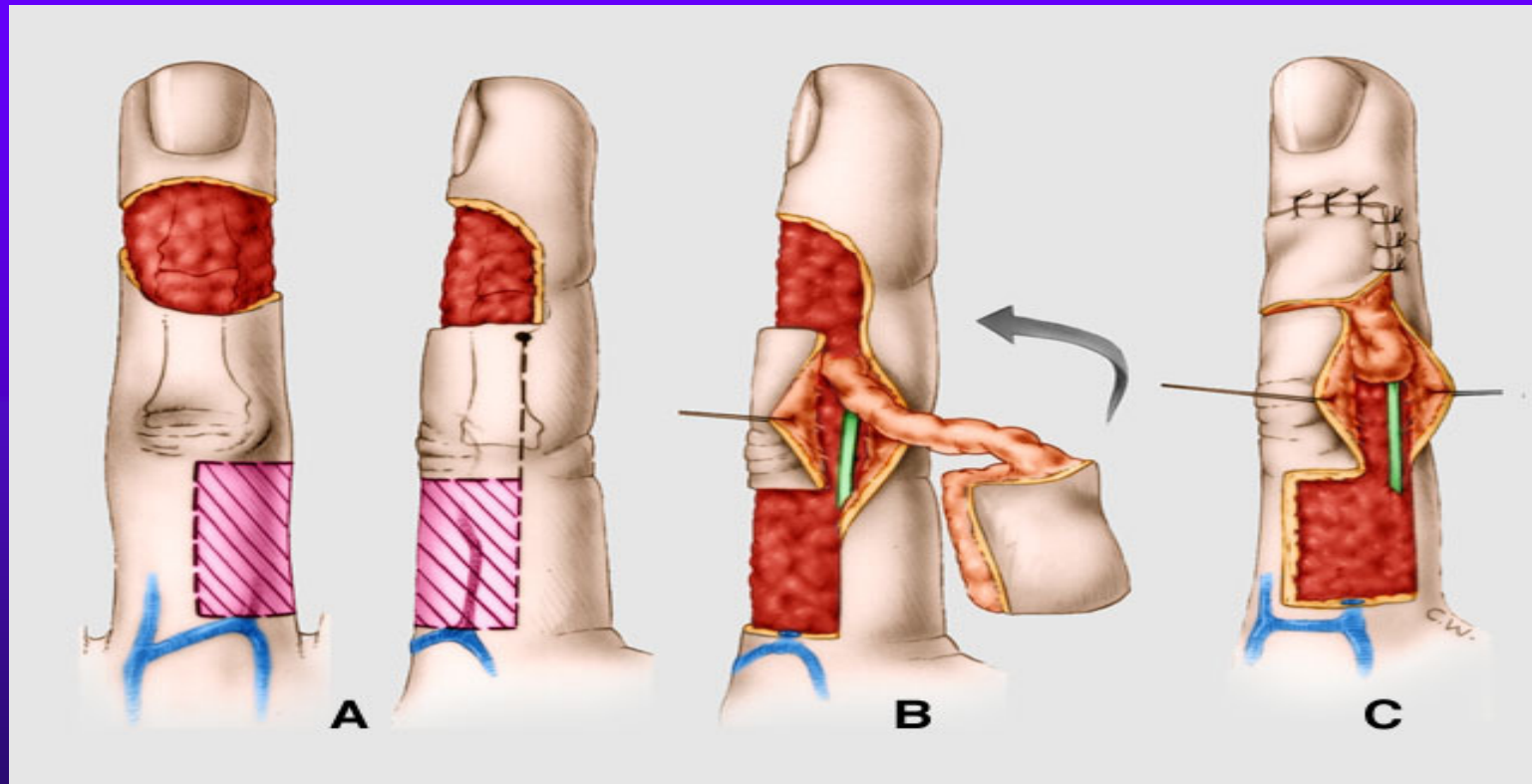


Dtto - pretoceni laloku & kozni  
step v jedne dobe

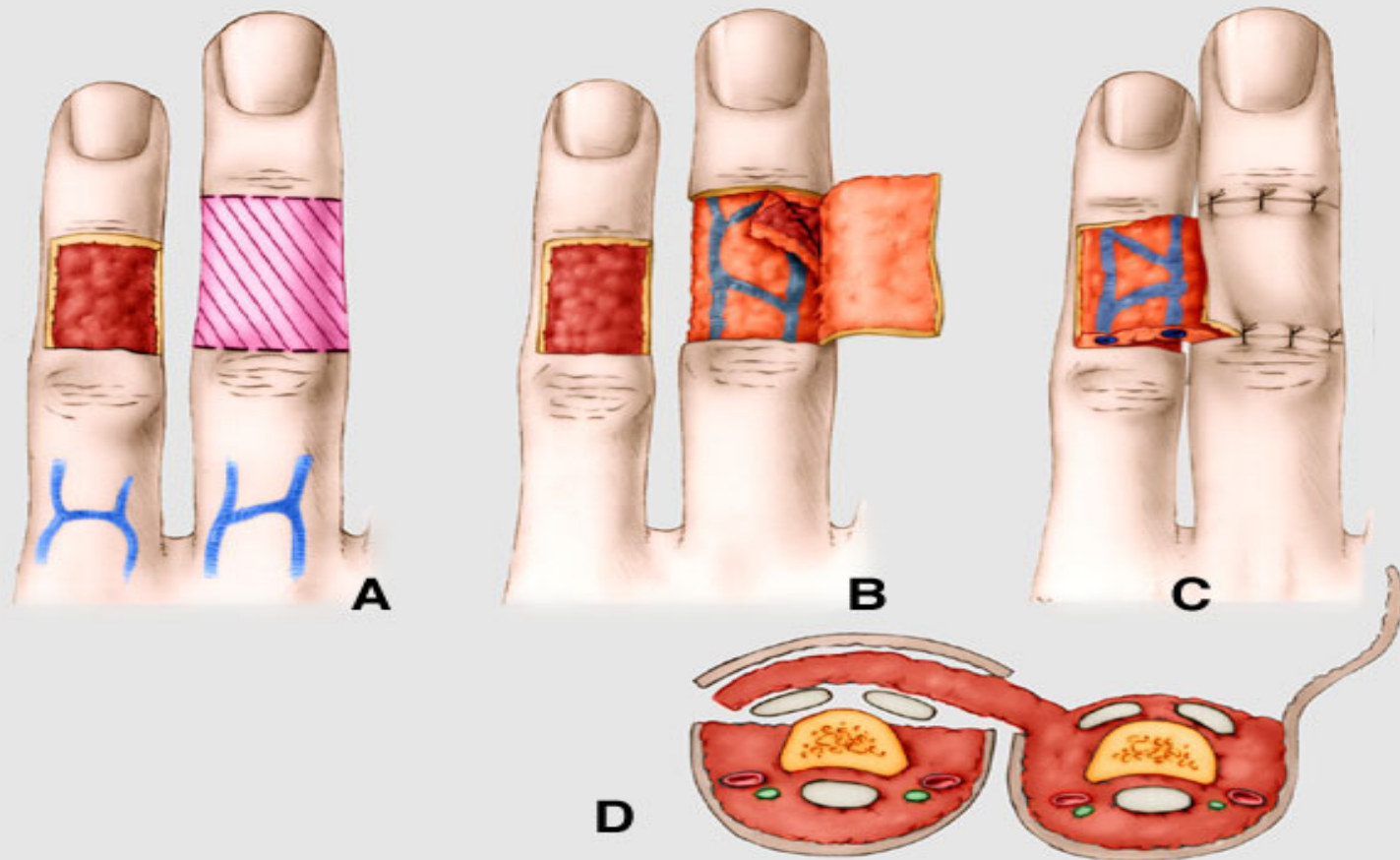




# Stopkaty nesensibilizované lalok « à contrario » pro dorsální ztrátu kožního krytu

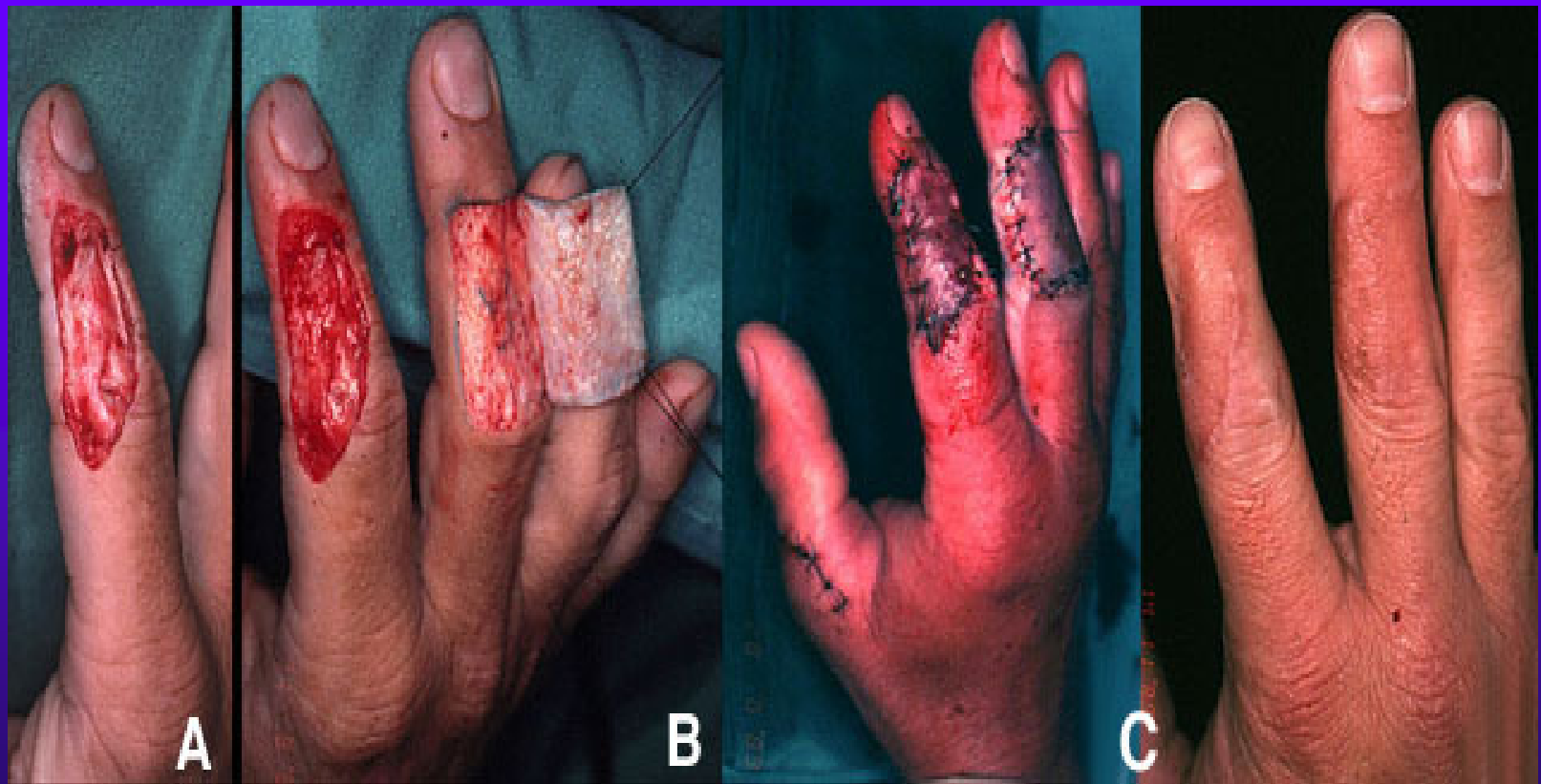

# Desepidermizovany cross finger

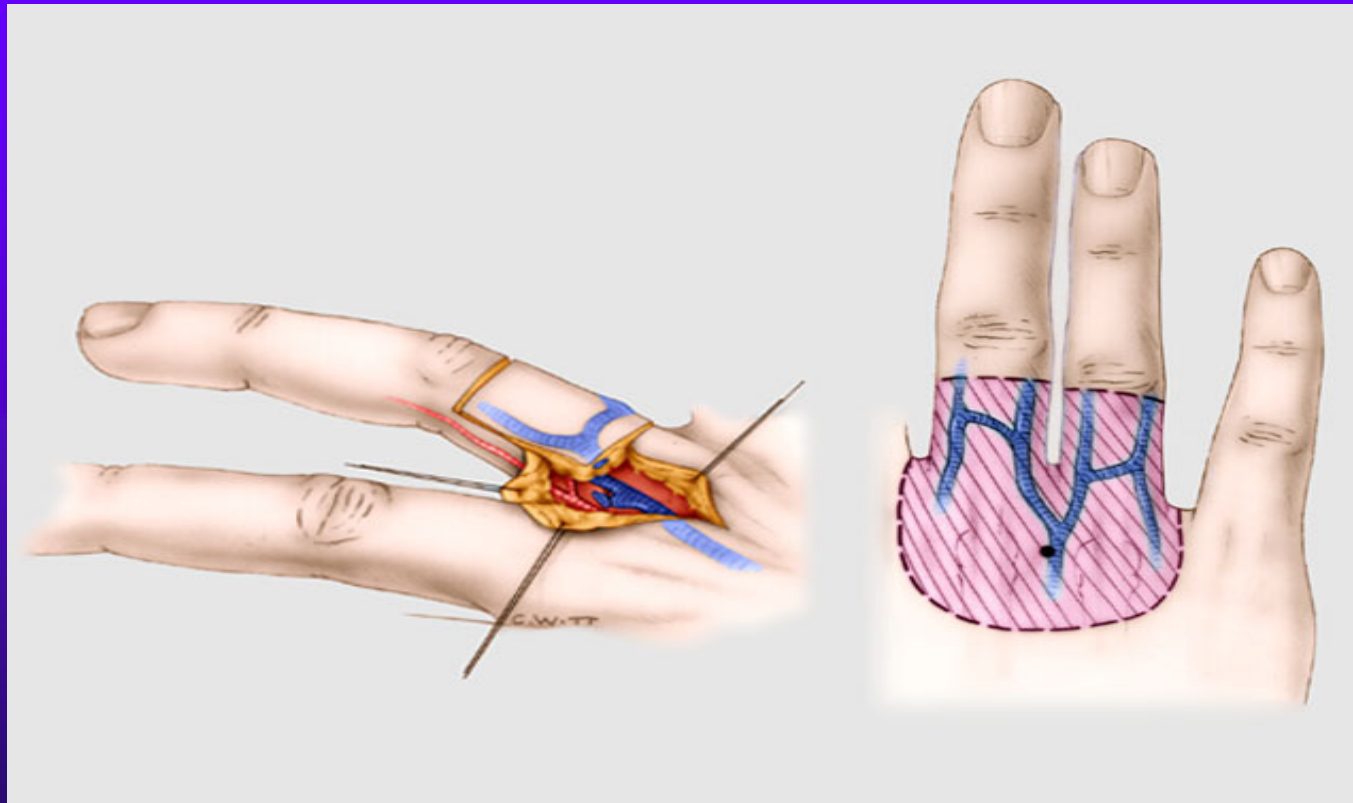




dtto

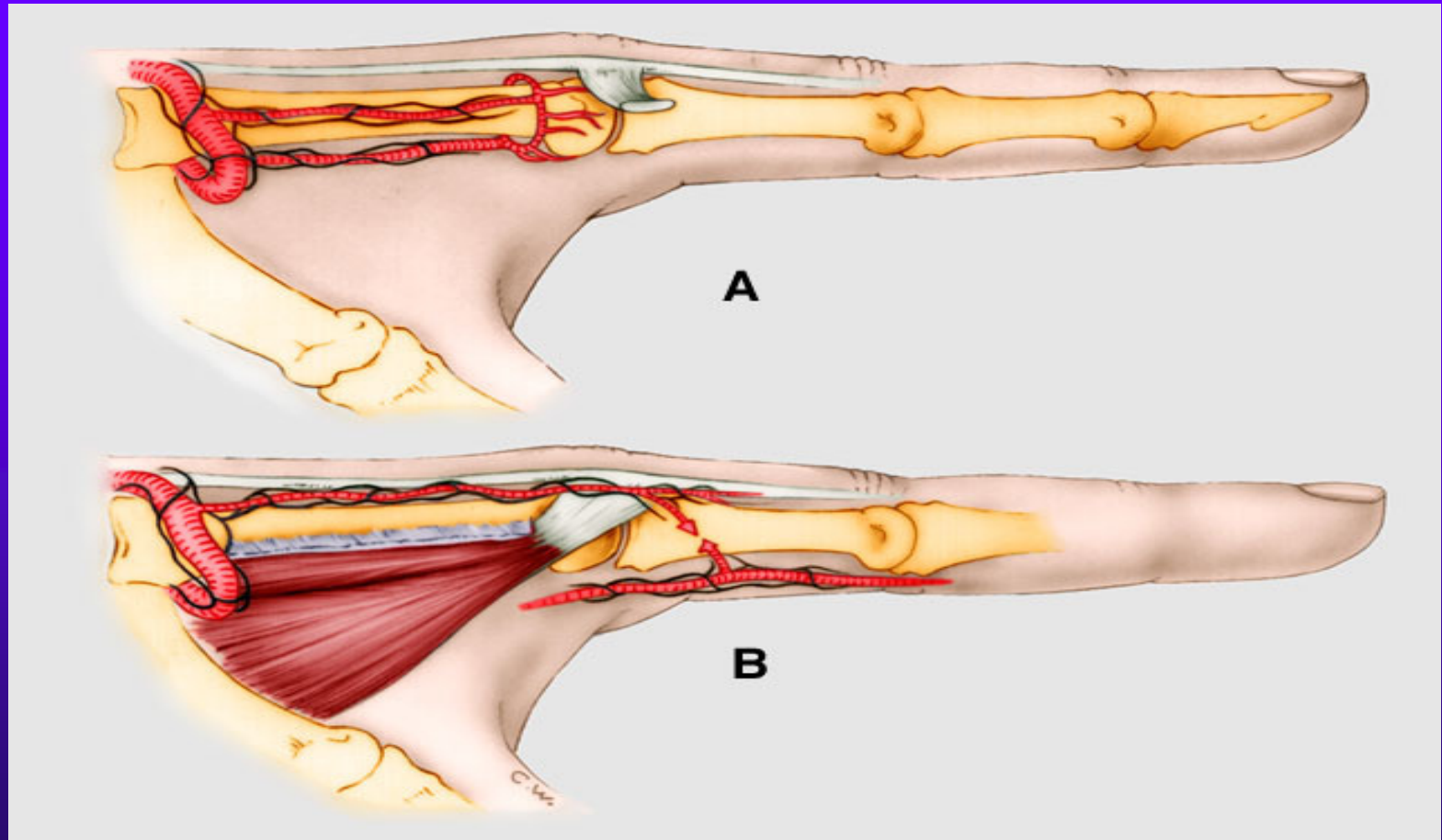


Metacarpalni lalok 3 a 4  
intermetacarp.prostoru (zalozeny  
na ascendentni vetvi art.colat.



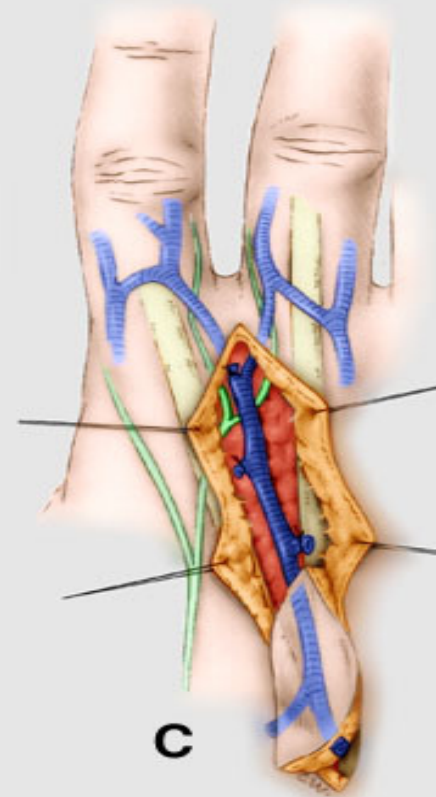
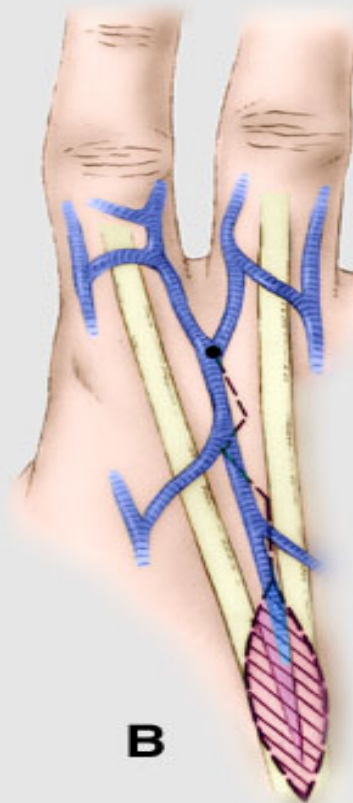
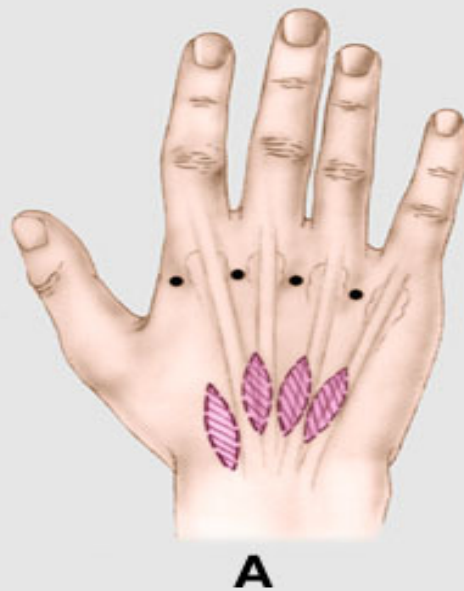

# Vascularizace dorsa metacarpu

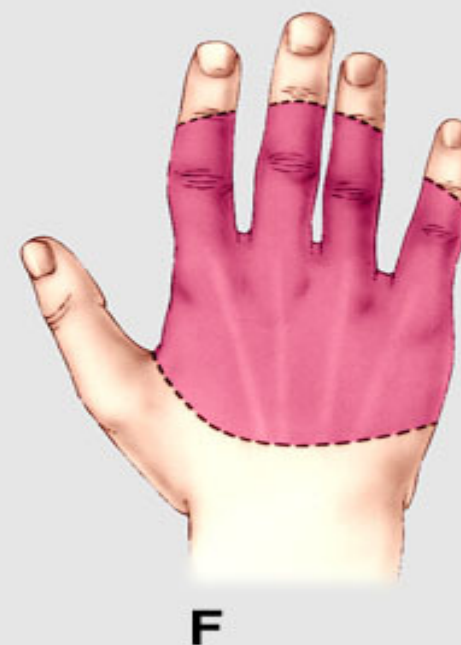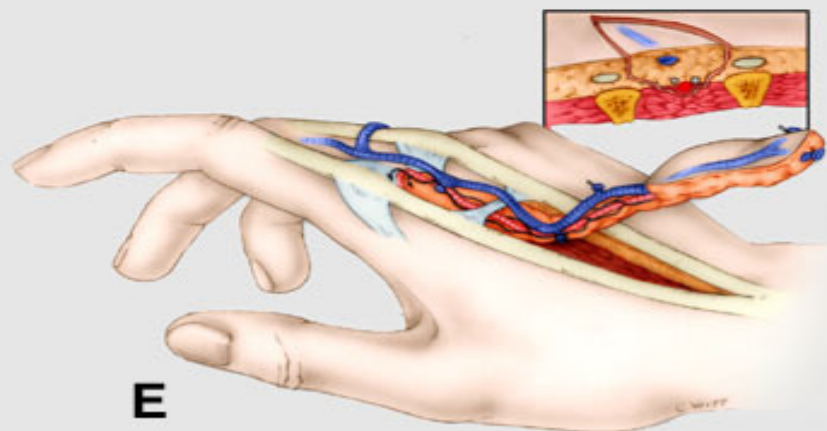
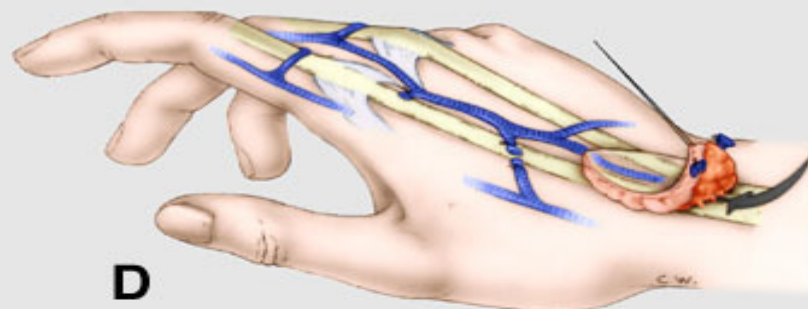




# Dorsalni intermet. stopkaty lalok à contrario



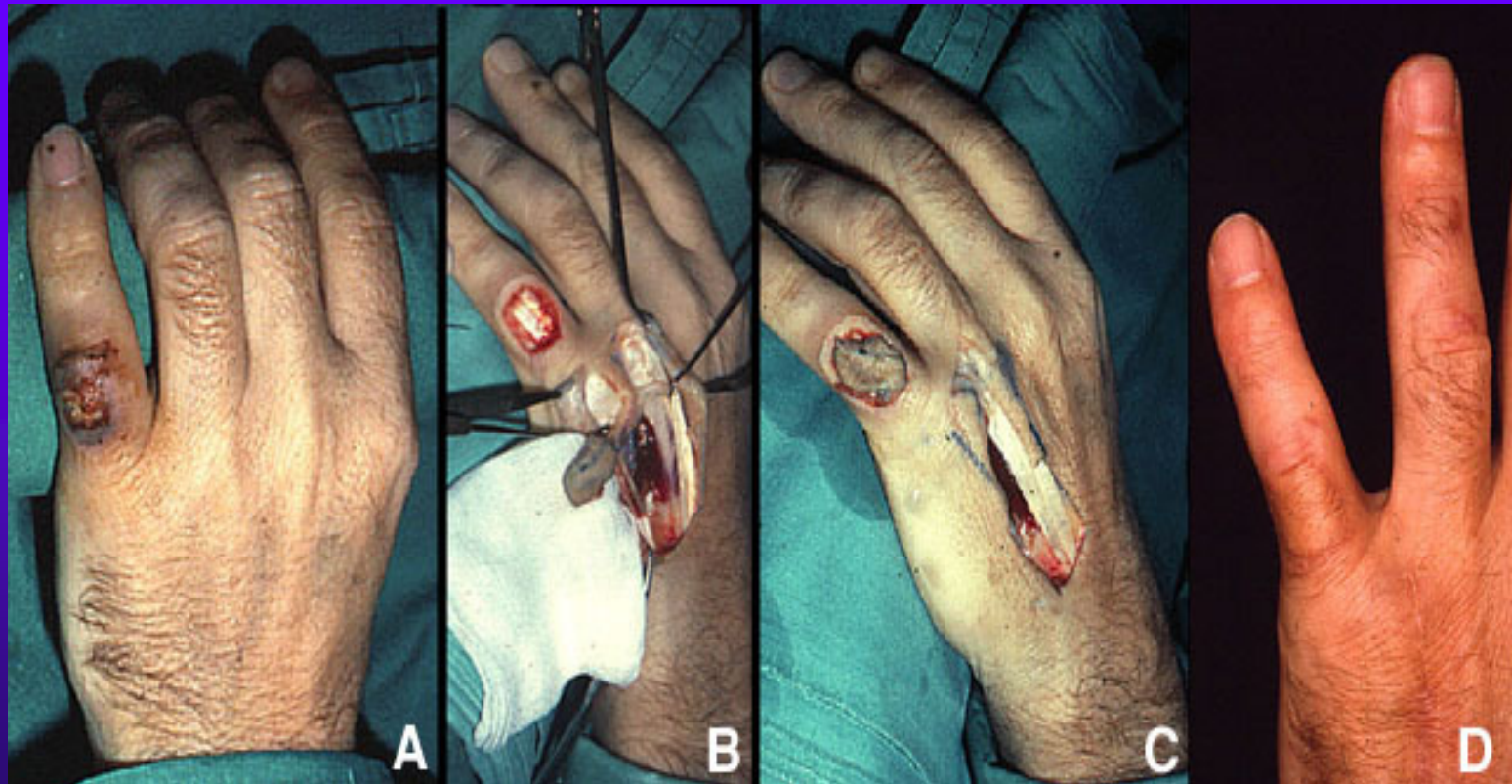
# Cevni stopka vzata i s fascii dorsalnih inteross.svalu



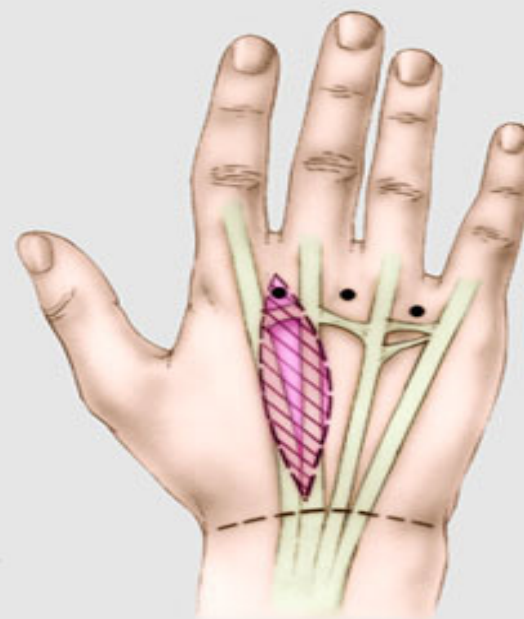
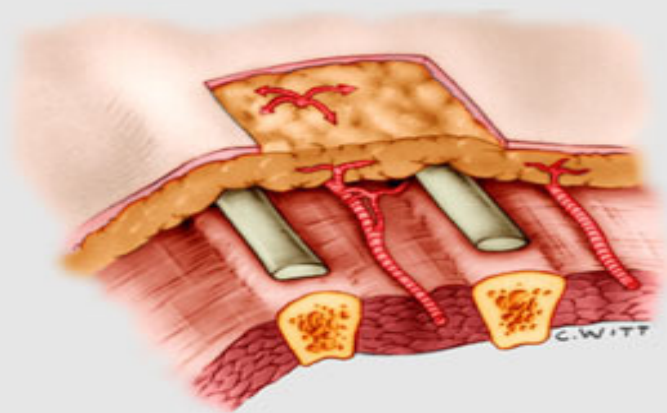




dtto

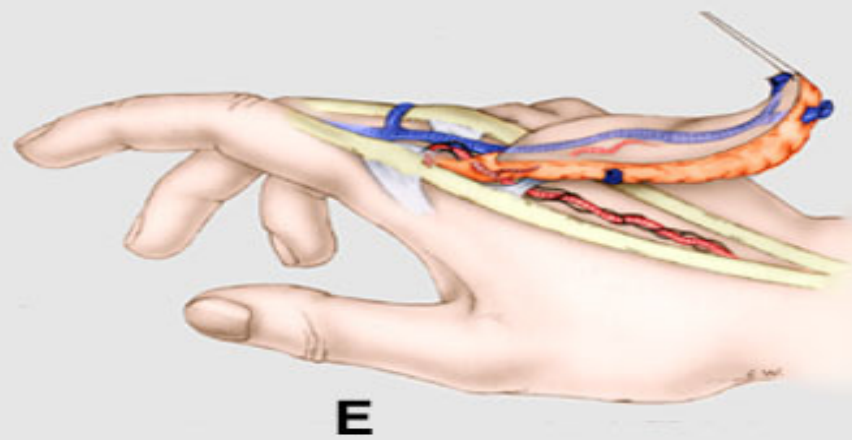
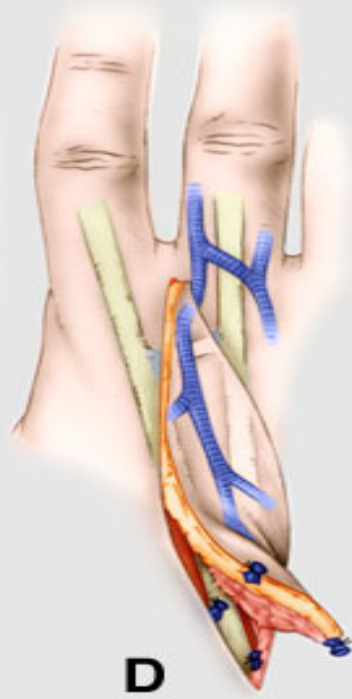
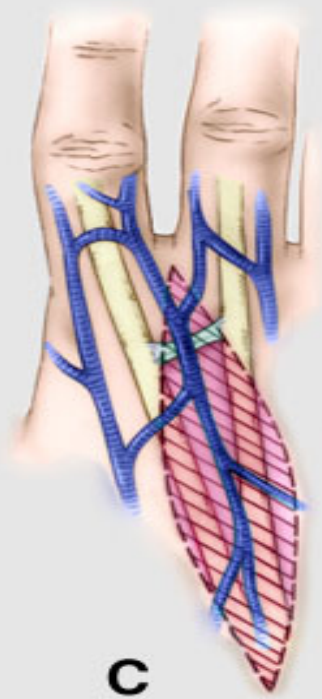


# Dorsalni stopkaty lalok zalozeny na intermetacarp.perforantech



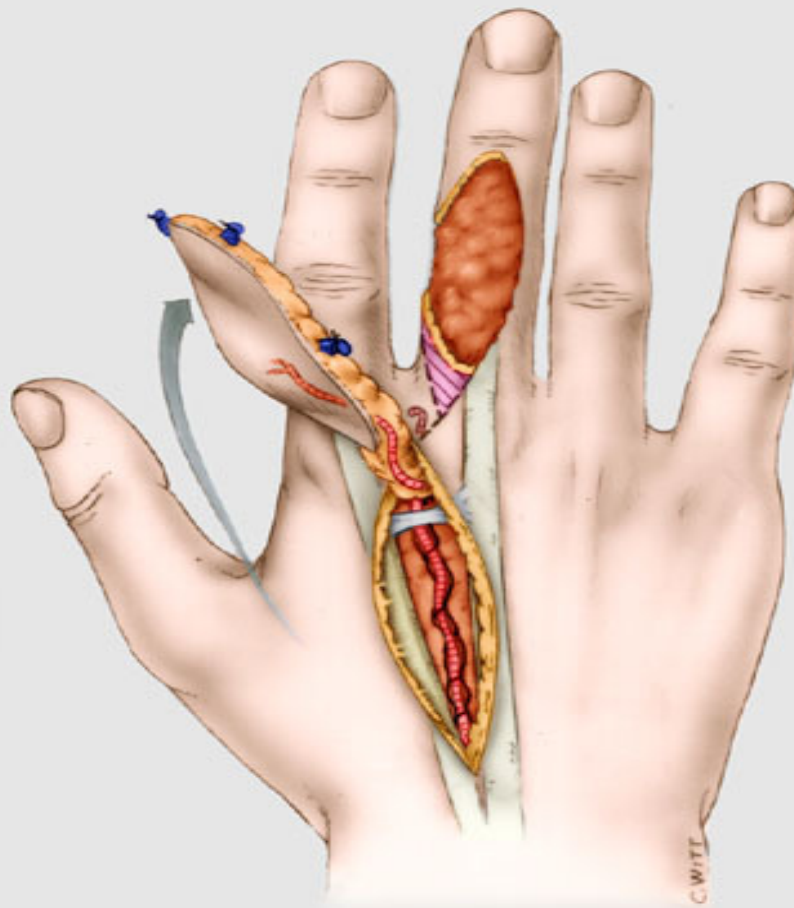


Dtto

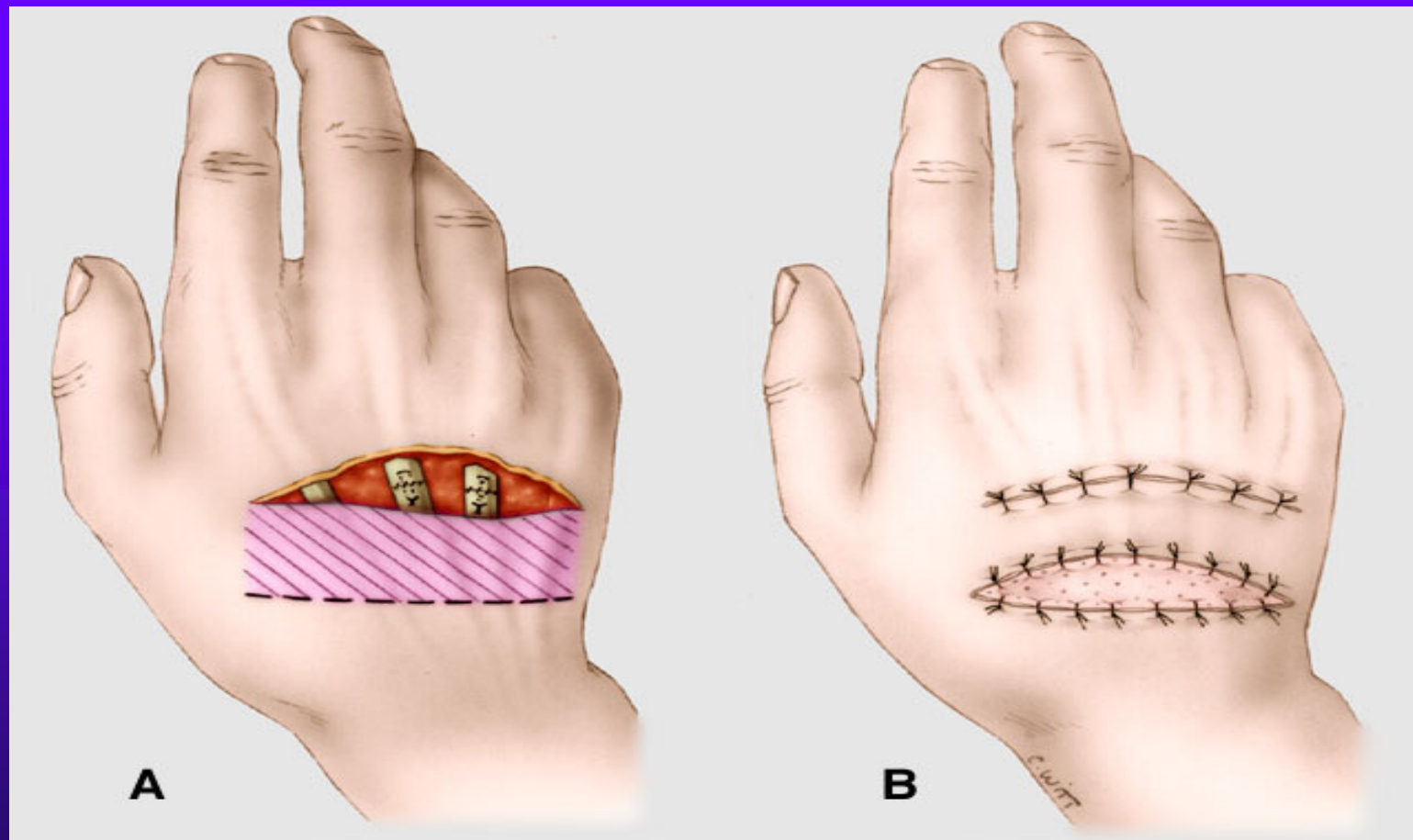




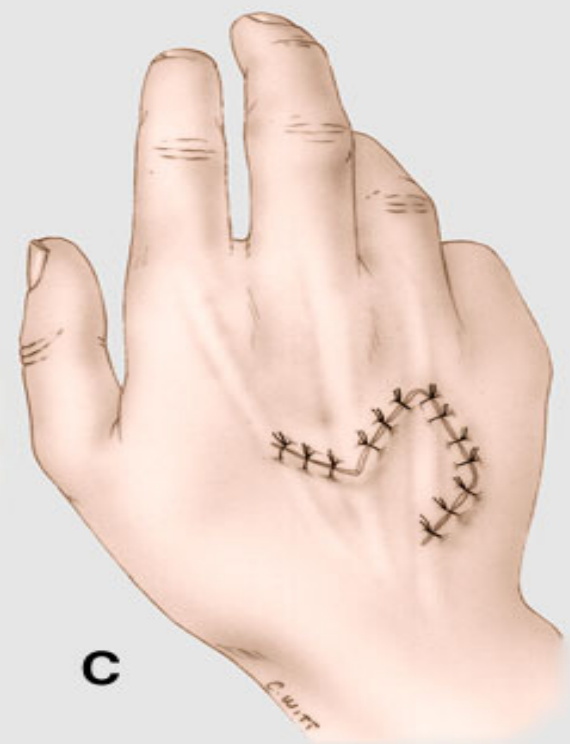
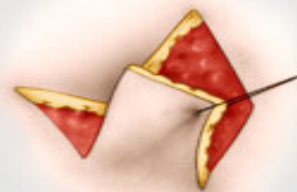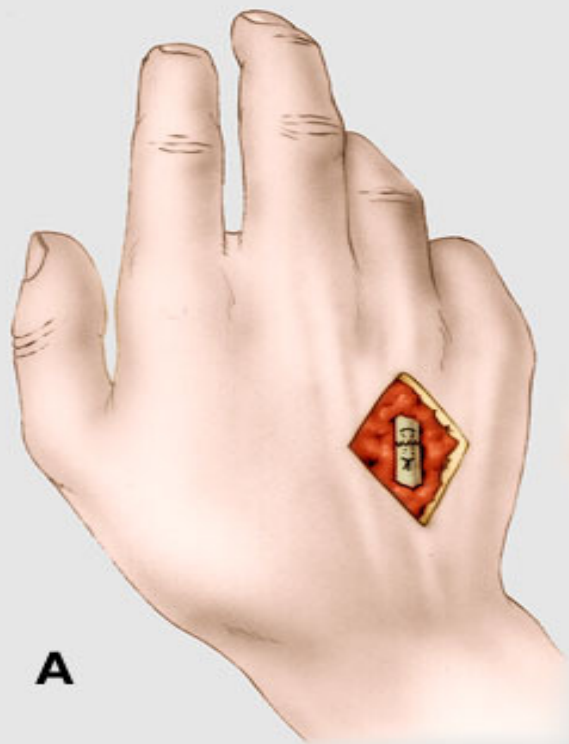Dtto, bod rotace distalne od  
juncturum tendineum



# Posuvny lalok pro ztratu kuze na dorsu ruky « posun & step »



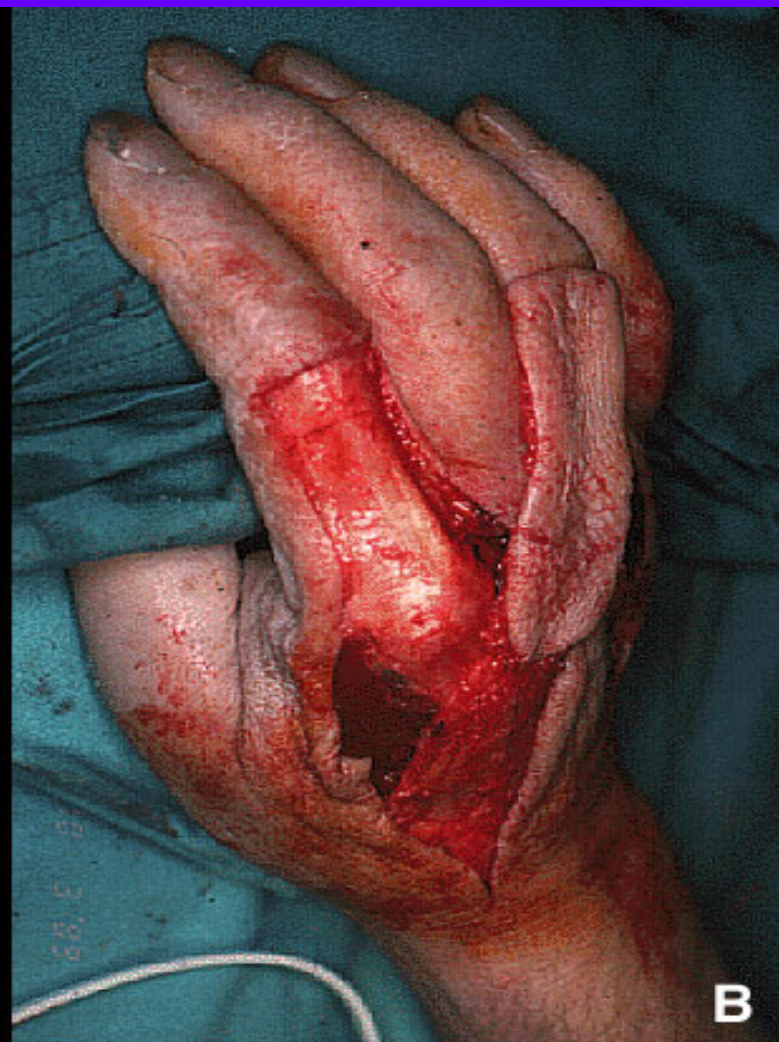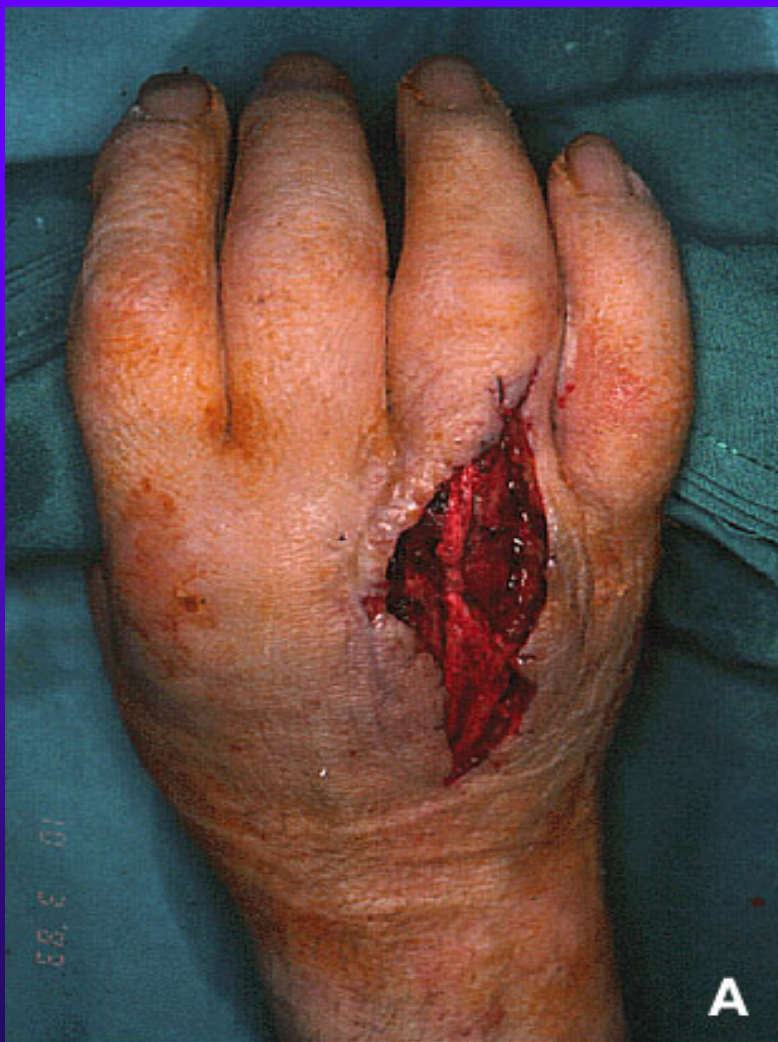# LLL plastika, rhomboid plasty, LLL Dufourmentel





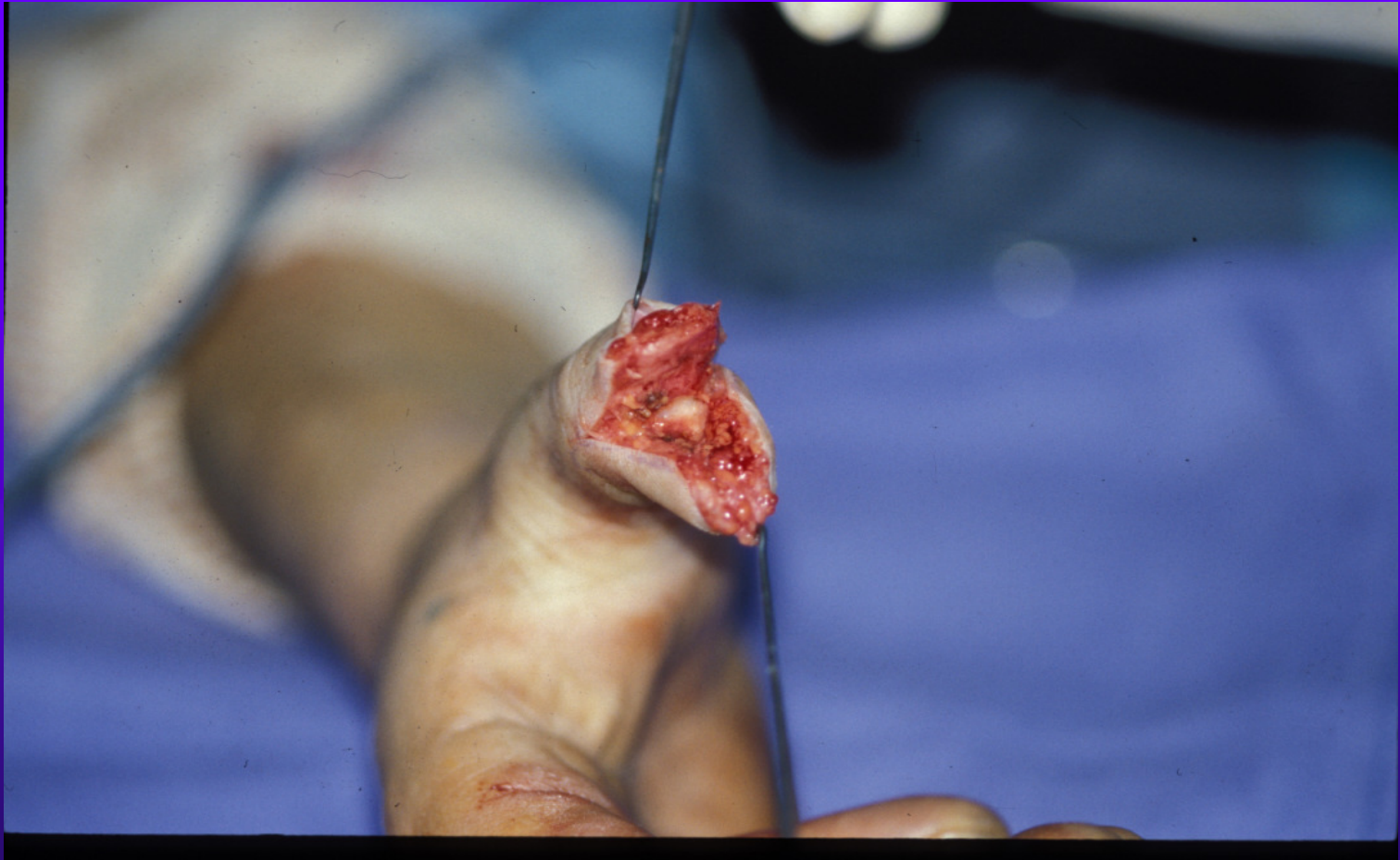

?

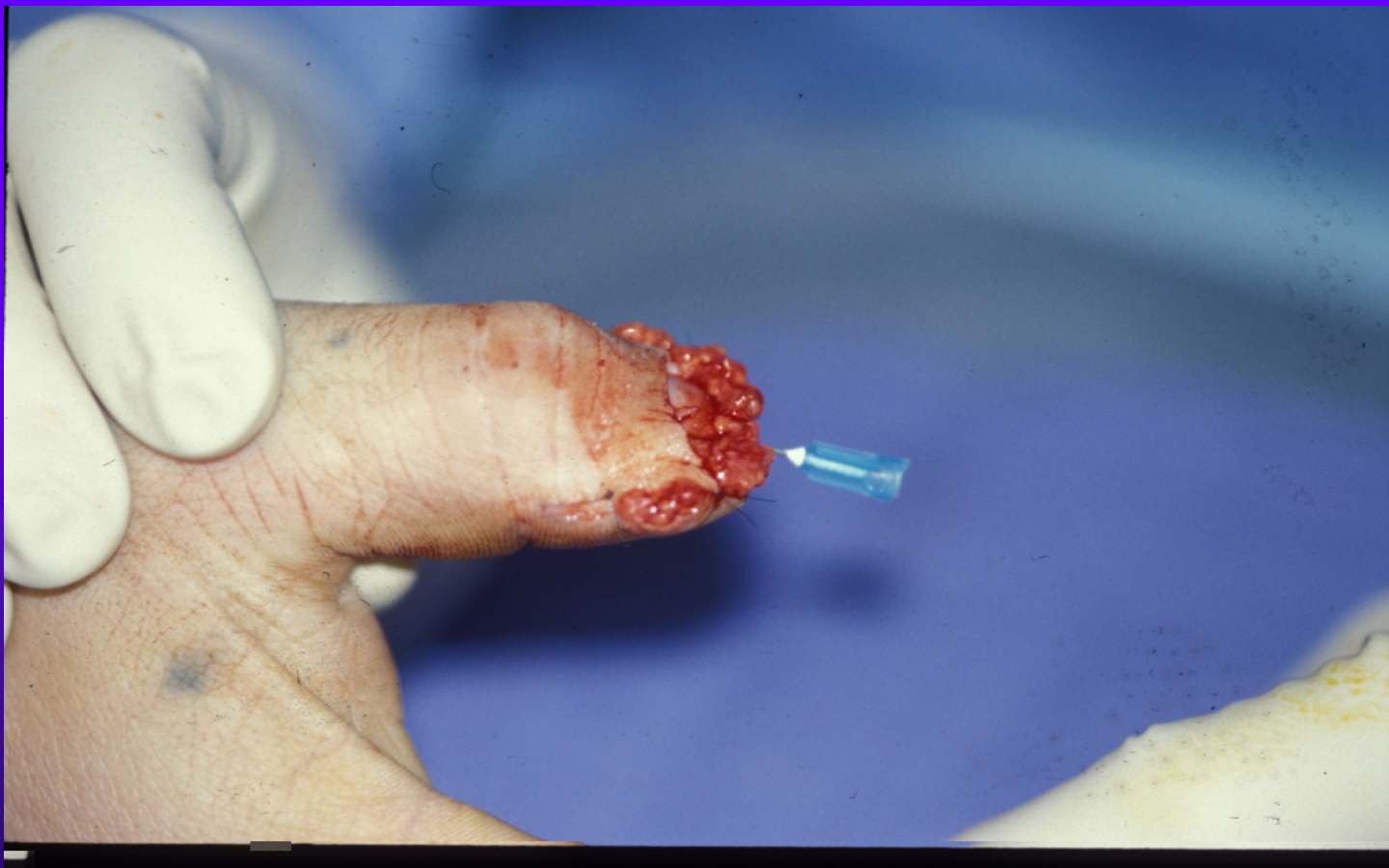



?







ERROR: undefined  
OFFENDING COMMAND: "mdG+\*h!7G=\$s4I~  
STACK: